

Corpi estranei gastrointestinali: lineari, metallici, ecogeni o solo gas?

Giliola Spattini
DVM, GP cert Cardio, CCRT, PhD, DECVDI



Diagnostic Mindset



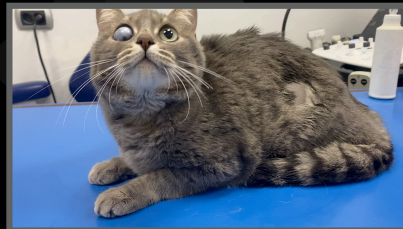Objectives

- Gastrointestinal FBs can be challenging
- Some more than others



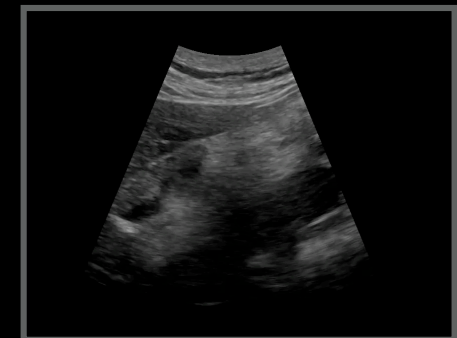
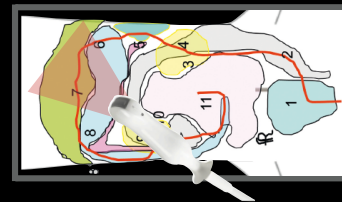
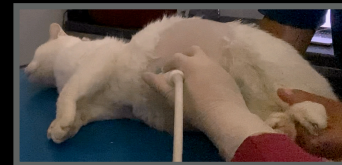Dori, DSH, FS, 2 years

- She had a viral infection when she was a kitten
- Chronically vomiting in the morning
- Resolved with dietary change
- Relapsed when the owner tried new food
- Not responding any more



Dori, FS, 2 years

Probe position in a different patient



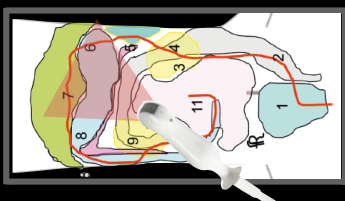
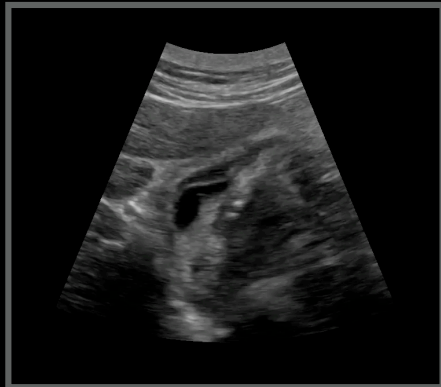
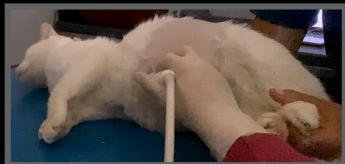7-6

Dori, FS, 2 years



Probe position in a different patient

7-6

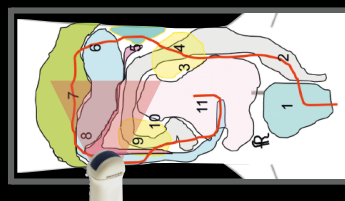
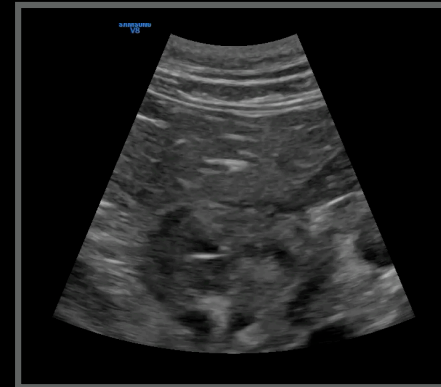
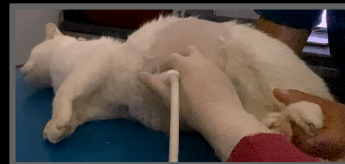

Dori, FS, 2 years



Probe position in a different patient

7-6

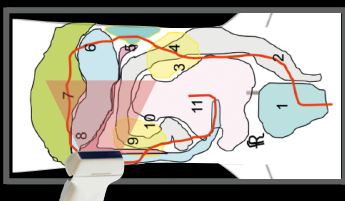
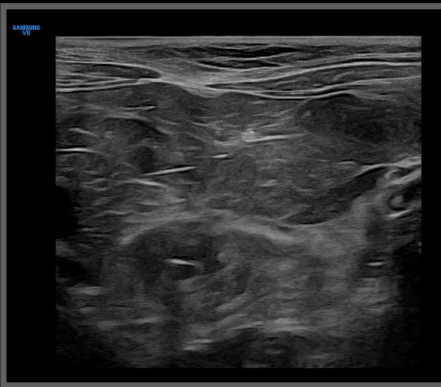
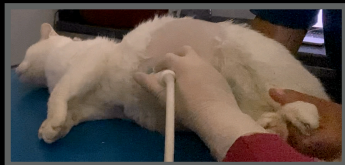

Dori, FS, 2 years



Probe position in a different patient

7-6

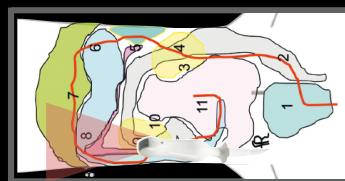
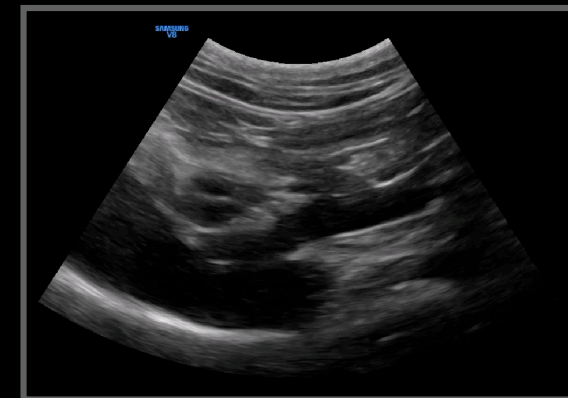
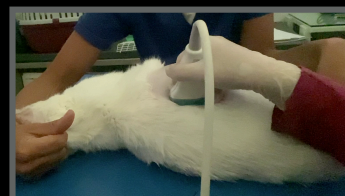

Dori, FS, 2 years



Probe position in a different patient

8'

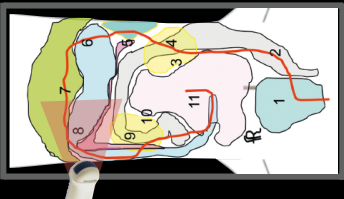
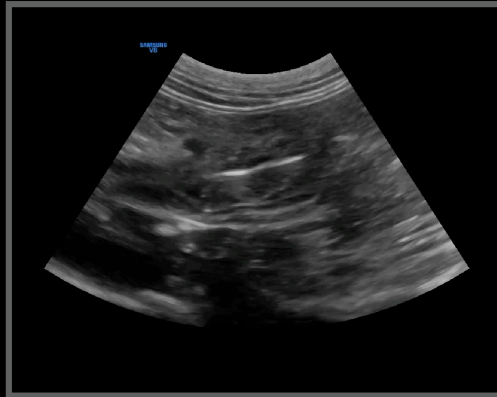
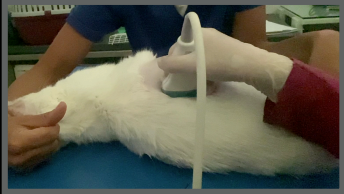


Dori, FS, 2 years



Probe position in a different patient

8'

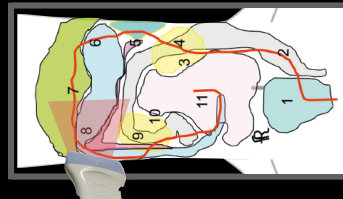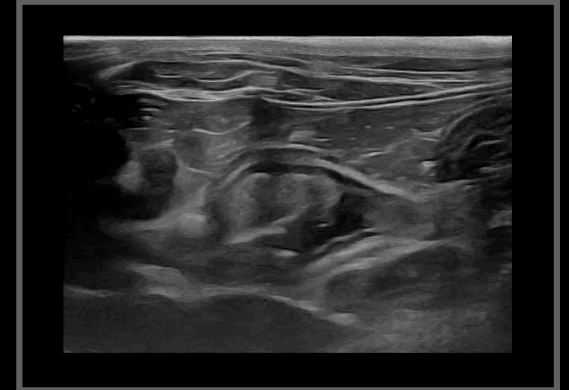
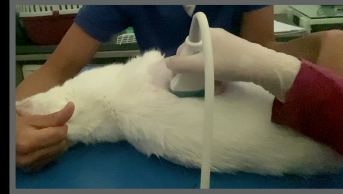


Dori, FS, 2 years

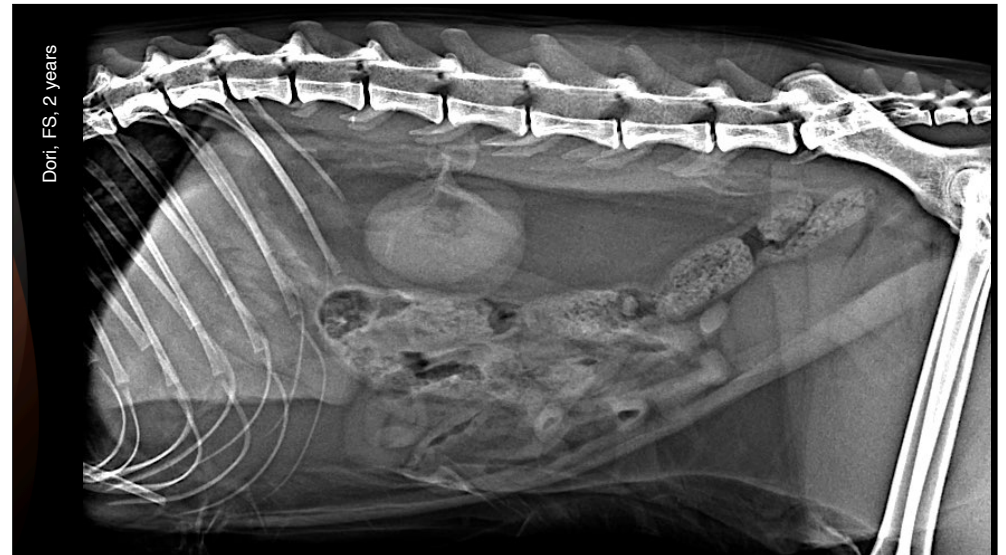
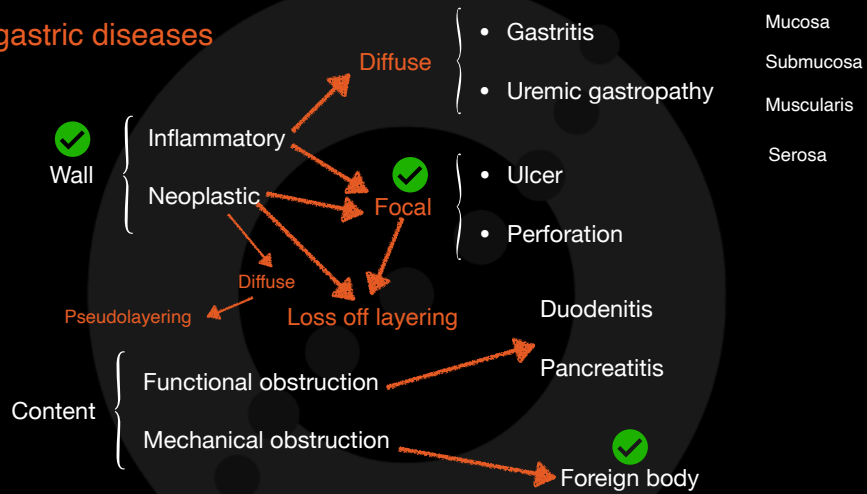


Probe position in a different patient

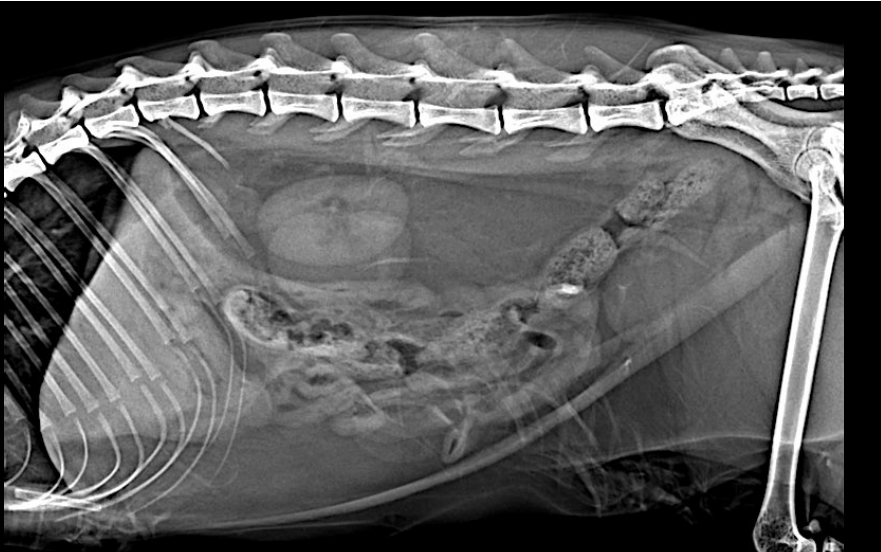8'



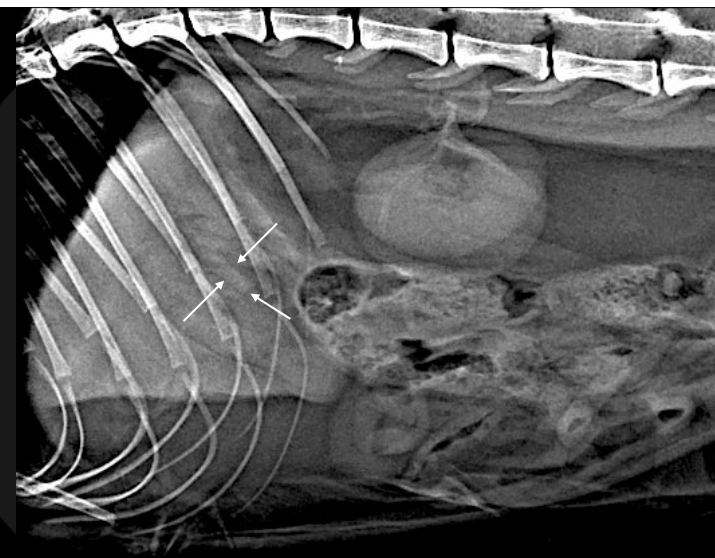
The gastric diseases



Dori, FS, 2 years



Dori, FS, 2 years



Dori, DSH, FS, 2 years

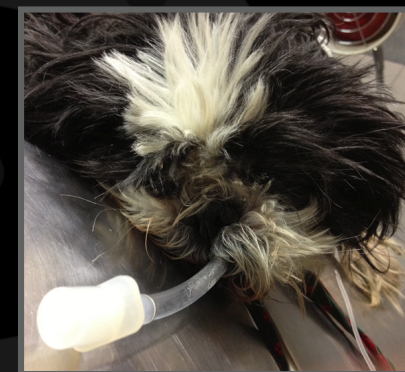- Dori went back to the referring veterinarian
- Three days later, an endoscopy was performed
- Several GE biopsies confirmed an underlying moderate lymphocytic-plasmacytic chronic gastro-enteritis

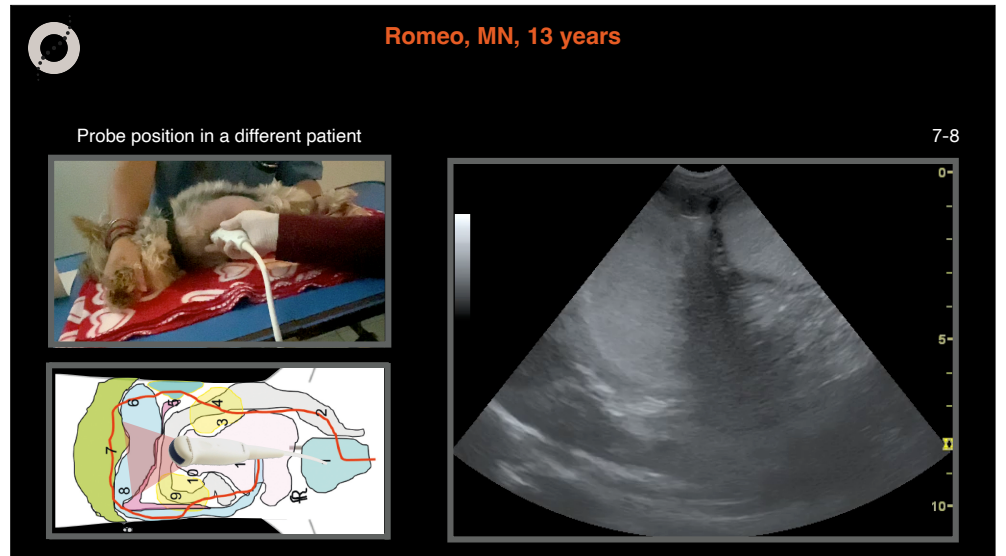
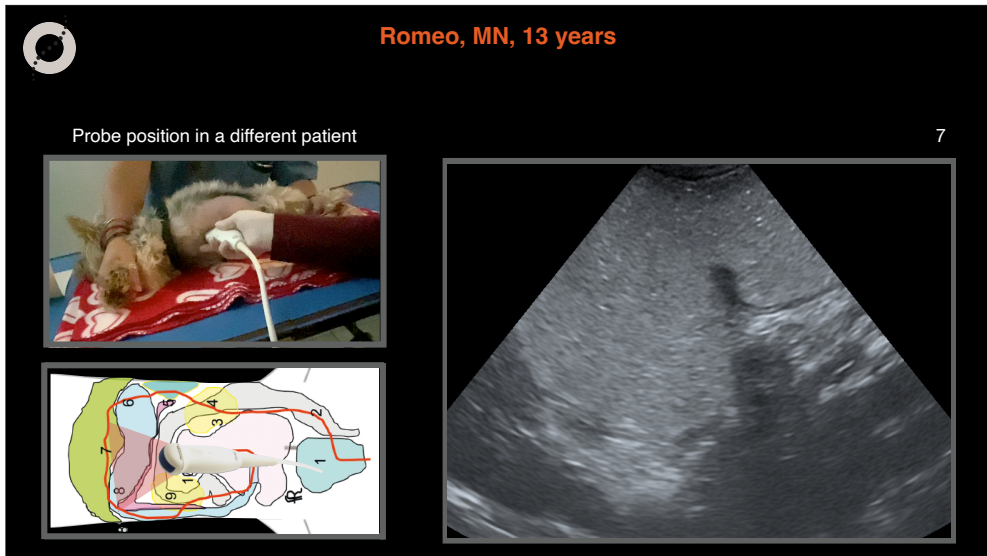
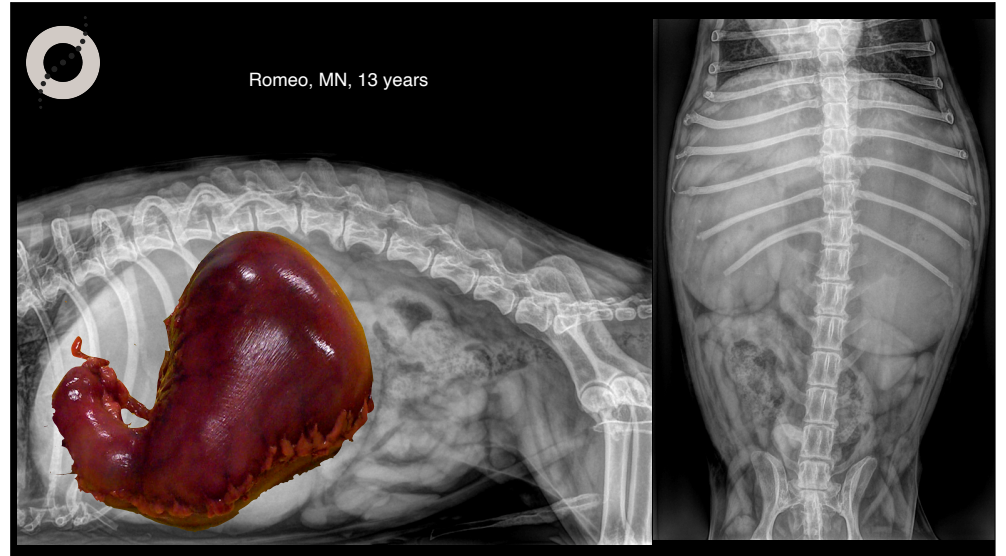
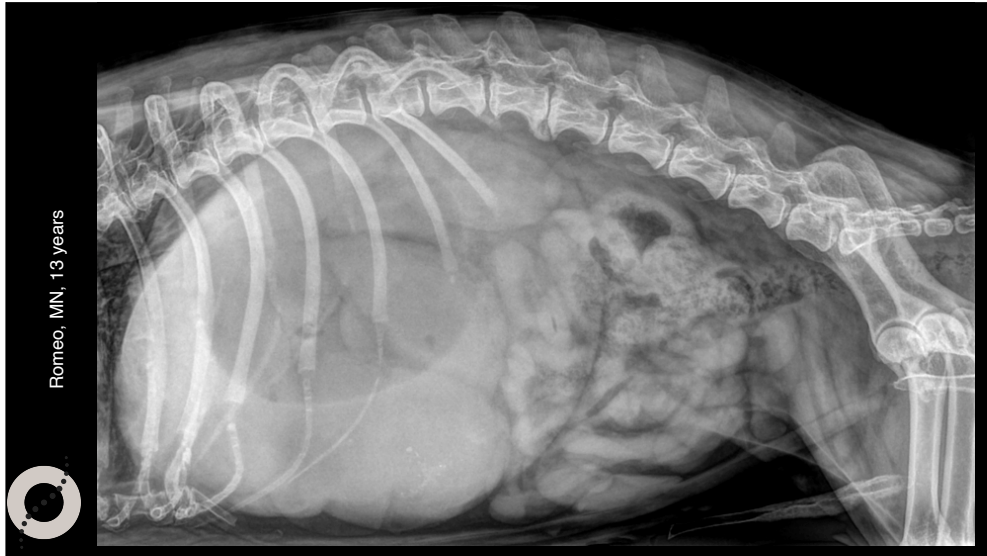


- The FB was removed

Romeo, Shitzu, MN, 13 years

- History of chronic vomiting
- Progressively worse since last month

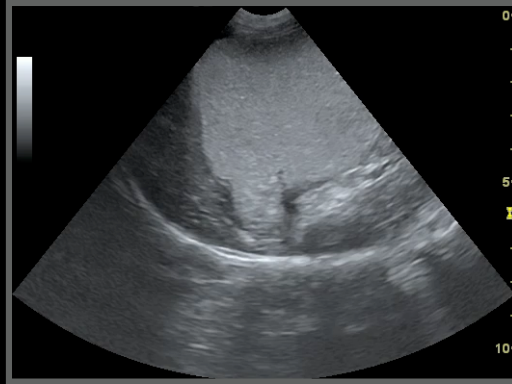
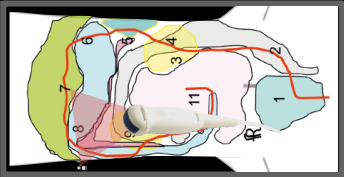




Romeo, MN, 13 years

Probe position in a different patient

7-8

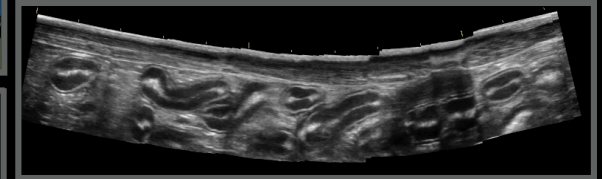
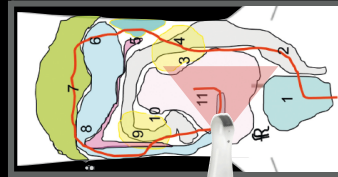
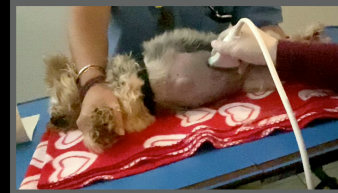
Romeo, MN, 13 years



Probe position in a different patient

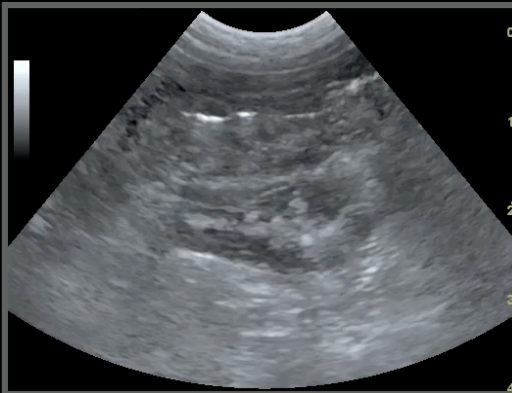
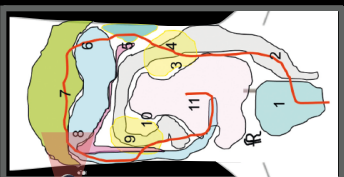
7-11



Romeo, MN, 13 years

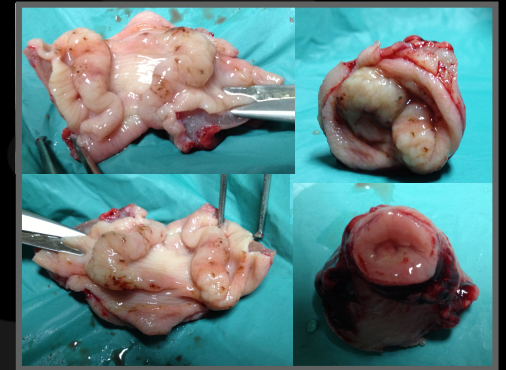
Probe position in a different patient

8'



Romeo, Shitzu, MN, 13 years

- Severely hypertrophied pyloric mucosa
- Partial gastric obstruction
- Pyloroplasty and histology



Bea, Dachshund, FS, 3 years

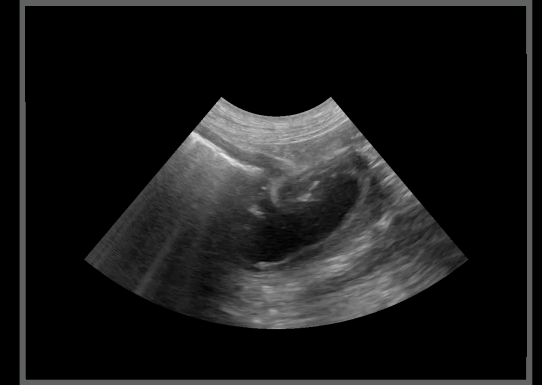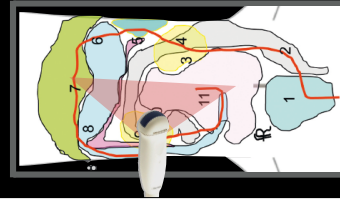
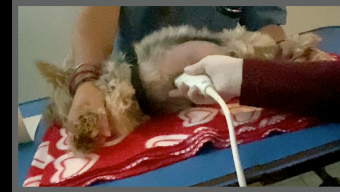- Trash scavenger
- She ate the cat's poo yesterday
- Vomiting and not eating



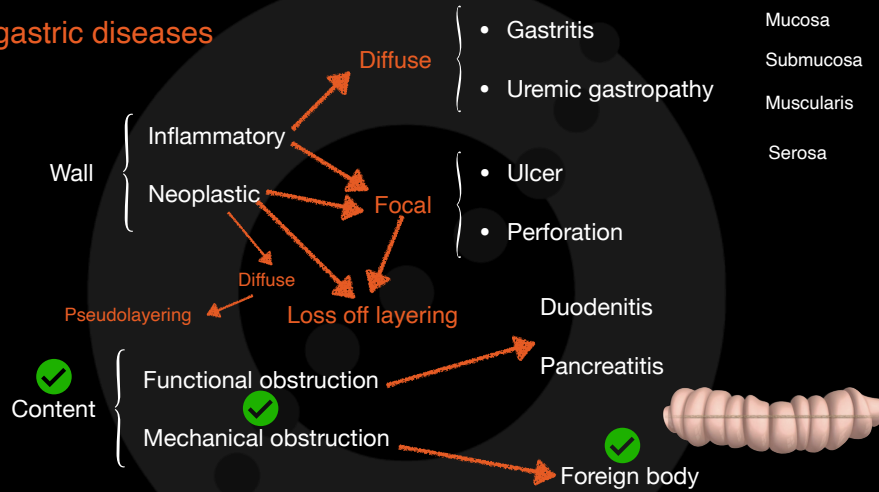
Bea, FS, 3 years

Probe position in a different patient

7-11

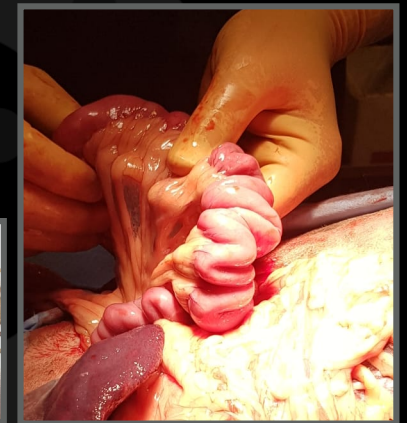


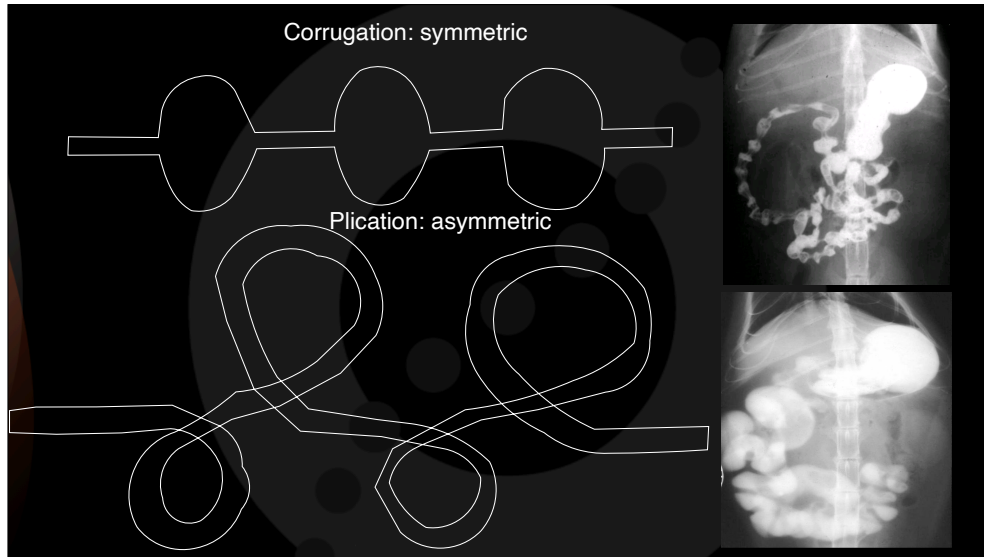
The gastric diseases



Bea, Dachshund, FS, 3 years

- Surgical removal of the linear FB





Louie, Vizsla, MN, 3 years

- 24h history of vomiting
- Not responding to treatment
- On a strict diet for a sensitive stomach

This slide introduces Louie, a 3-year-old Vizsla from Minnesota. It lists his clinical history: a 24-hour history of vomiting, no response to treatment, and a strict diet for a sensitive stomach. A photograph of Louie sitting is shown on the right.

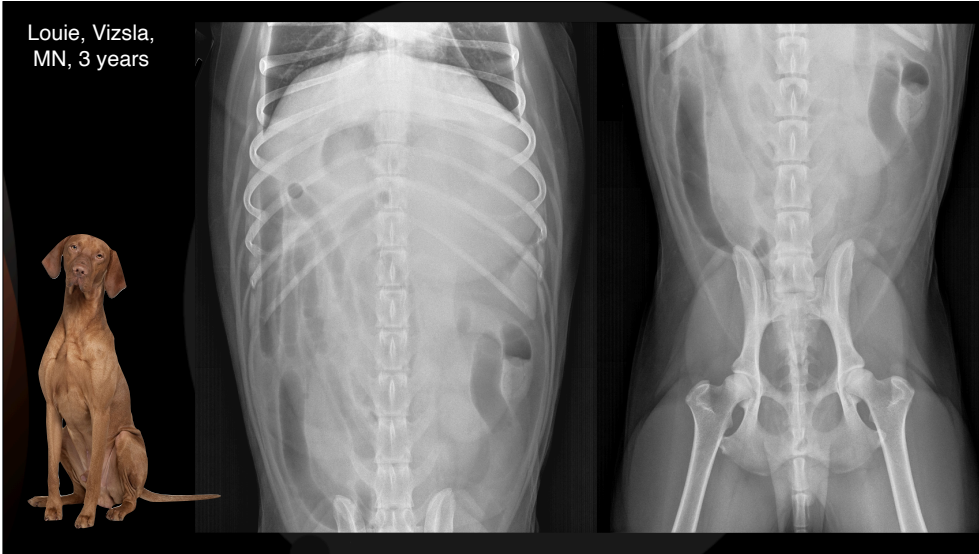Louie, Vizsla, MN, 3 years

This slide shows a lateral abdominal radiograph of Louie. The image displays the internal organs, including the stomach and intestines, and the spine. A small photograph of Louie sitting is included in the bottom left corner for identification.

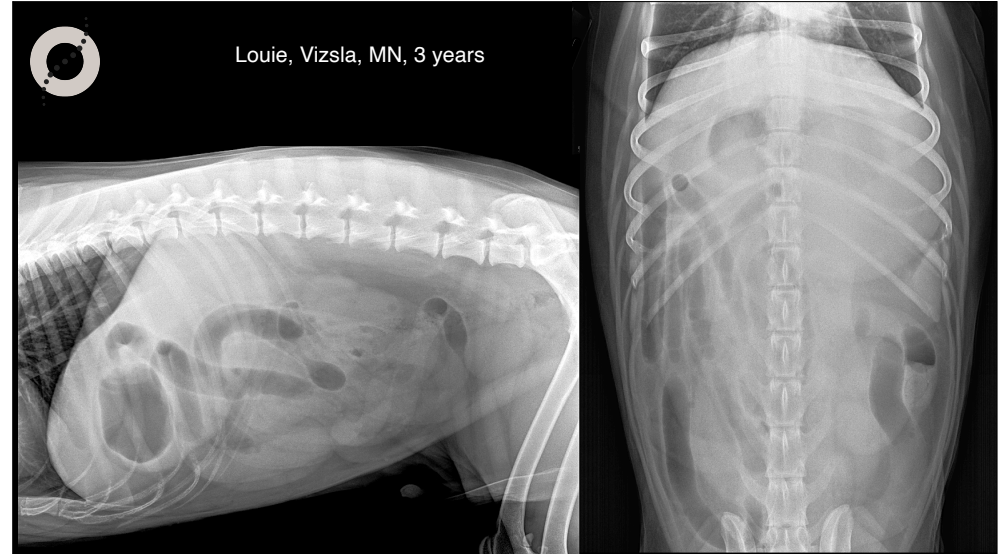Louie, Vizsla, MN, 3 years

This slide shows another lateral abdominal radiograph of Louie, providing a different view of the internal organs and the spine. A small photograph of Louie sitting is included in the bottom left corner for identification.

Louie, Vizsla, MN, 3 years



Louie, Vizsla, MN, 3 years



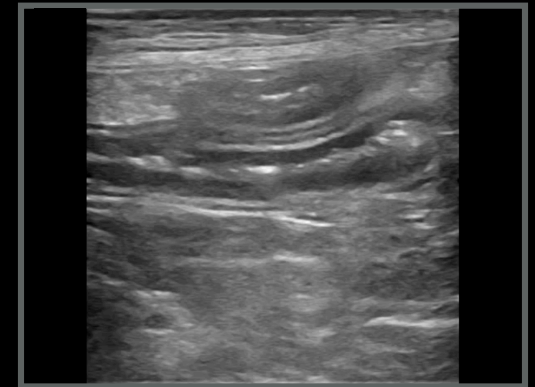
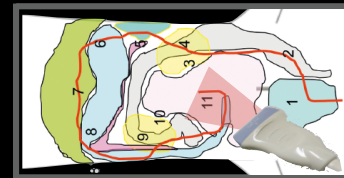
Your evaluation

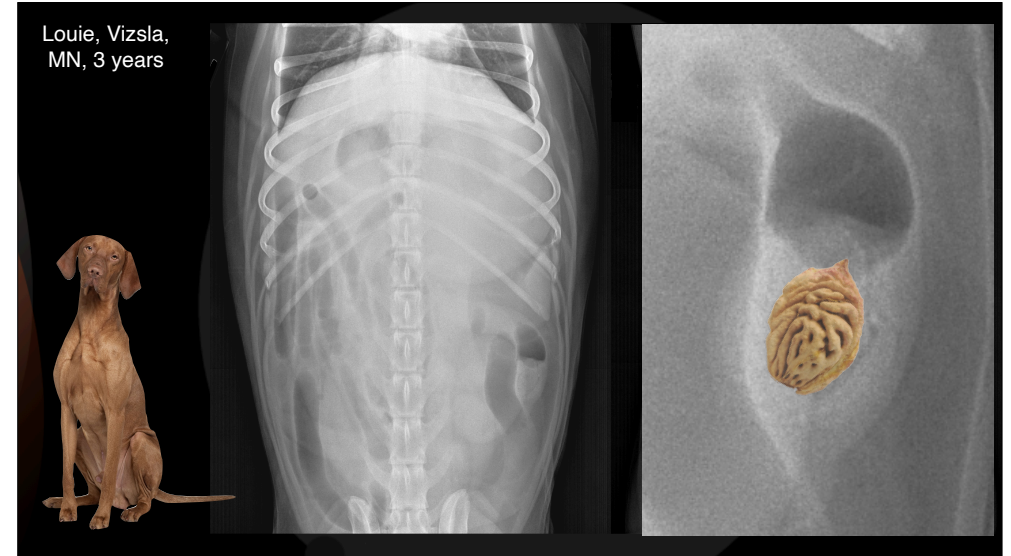
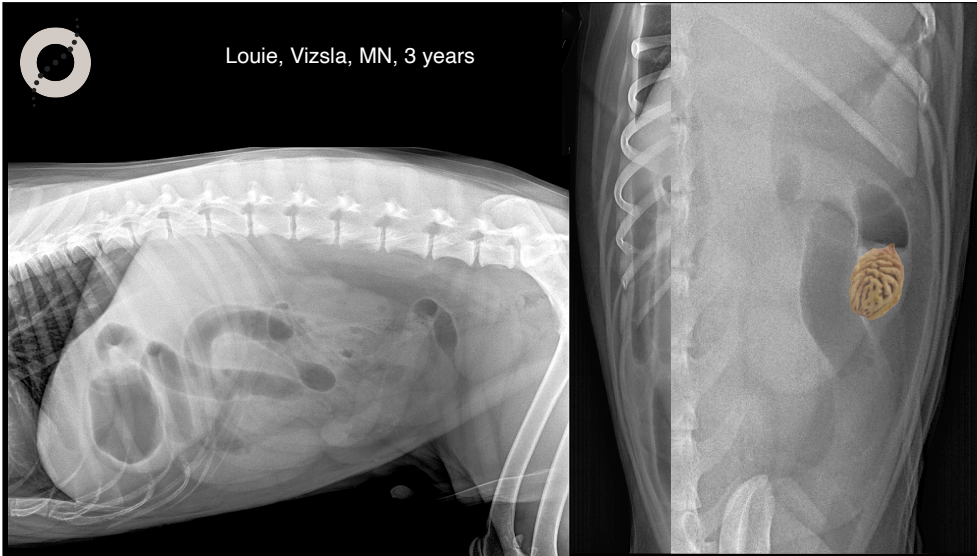
- Is there a foreign body?
- Is there gastroenteritis?
- Is there a gastrointestinal occlusion?



Louie, MN, 3 years

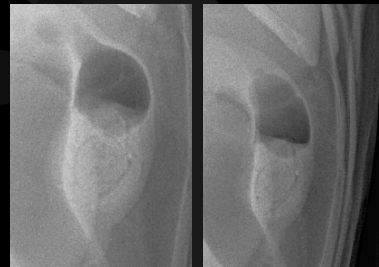Probe position in another patient





Key points

- Oval soft tissue structure
- Typical radiolucent curved lines
- Often only visible in one view




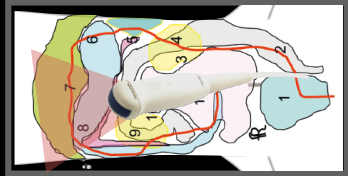
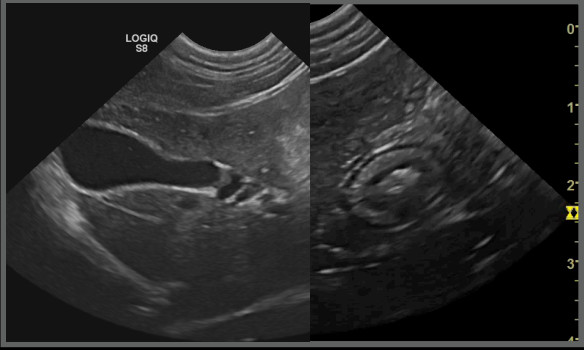
Tigro, DSH, MN, 6 years

- Chronic vomiting
- Very aggressive patient
- Sedation is planned




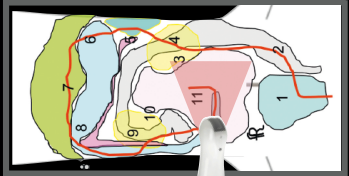

Tigro, MN, 6 years

Probe position in a different patient 7-8




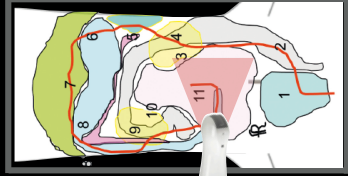

Tigro, MN, 6 years

Probe position in a different patient 11




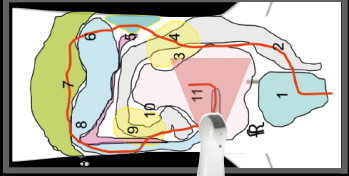

Tigro, MN, 6 years

Probe position in a different patient 11



Tigro, MN, 6 years

Probe position in a different patient 11

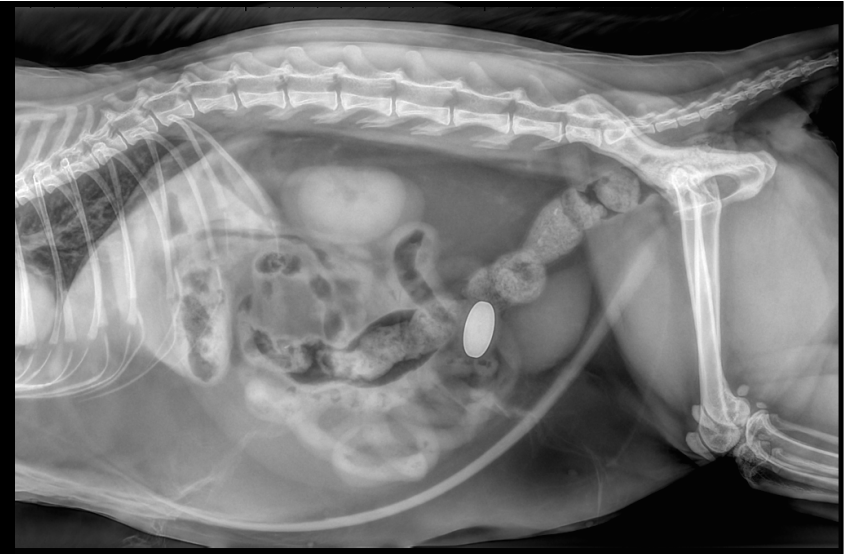

Your evaluation

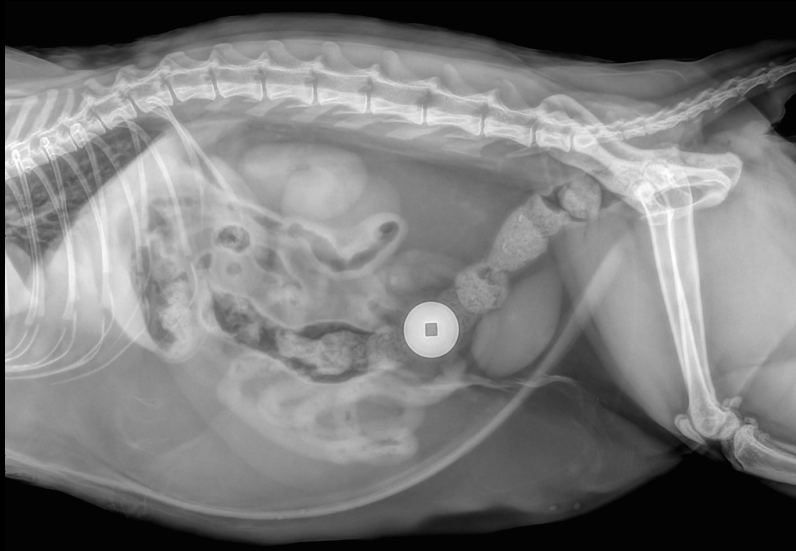
- Is there a focal peritonitis?
- Is there hepatitis?
- Is there a FB?




Tigro, MN,
6 years



Tigro, MN,
6 years



Tigro, MN, 6 years

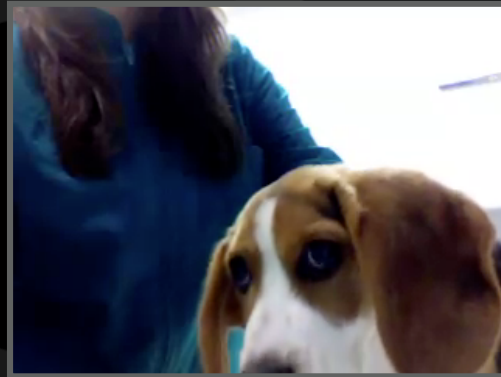

Bacco, Beagle, MI, 4 months

In the last two weeks decreased appetite

Lethargic

A swelling was noted by the owner in the right inguinal region



Bacco, Beagle, MI, 4 months

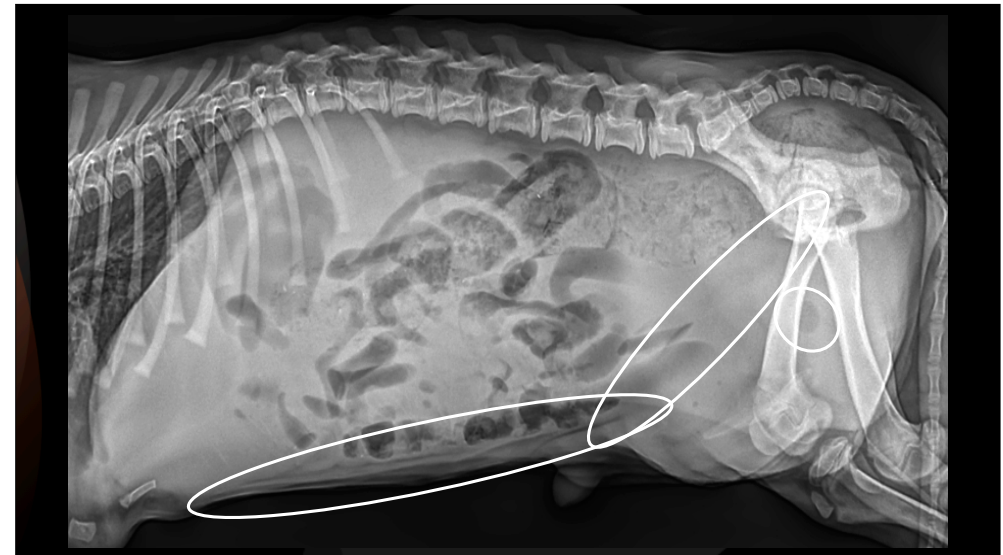
Blood work

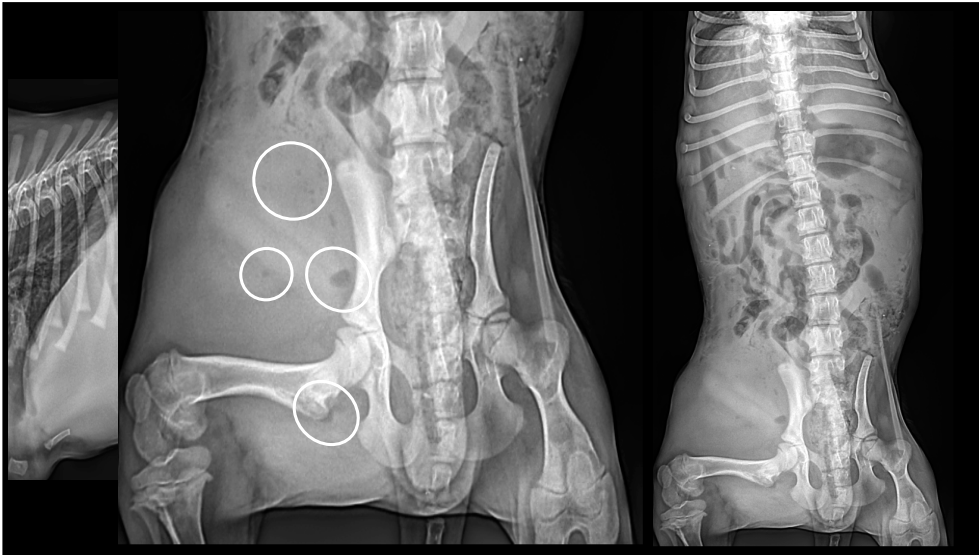
BACCO , BEAGLE M, 4 MESI	PAZIENTE	RIFERIMENTO	BACCO	PAZIENTE	RIFERIMENTO
RBC	4.97	5.50 – 7.90	WBC (X 10 ³ /ul)	39900	6000-16000
Hb (g/dl)	10.1	12.0-18.0	Neutr. Banda (/ul)	11172	0-300
Hct (%)	29	37-55	Neutr. Segm (/ul)	17955	3600-14000
MCV (fl)	58	60-76	Linfociti (/ul)	5586	720-5750
MCH(pg)	20	20-25	Monociti (/ul)	5187	0-1400
MCHC (g/dl)	35	32-39	Morfologia	Linfociti attivati +	Neutr. Tossici ++
RDW (%)	17.6	10.0-16.0			
Morfologia	Codociti +				

BACCO	PAZIENTE	RIFER.
N PLT (X 1000/ul)	211	120-350
MPV (fl)	9.7	8.0-12.3
PCT (%)	0.206	0.120-0.300
PDW (%)	23.9	10.0-27.0
Stima a vetrino	Adeguate	

Bacco, Beagle, MI, 4 months

BACCO			BACCO		
ALT (u/L)	11	15-50	Crea (mg/dl)	0.30	0.75-1.30
ALP (u/L)	157	20-105	Glu (mg/dl)	75	60-100
PROT. TOT.	6.4	5.5-7.7	Calcio (mg/dl)	9.3	8.0-12.0
ALB (mg/dl)	2.5	2.6-3.8	Fosforo (mg/dl)	6.9	2.1-6.2
GLOB (mg/dl)	3.9	2.6-4.5	Sodio (mEq/dl)	139	140-150
Rapp. A/G	0.6	0.7-1.2	Potassio (mEq/dl)	3.2	3.9-4.8
Colesterolo (mg/dl)	269	120-255	Rapporto Na/K	43	> 30
Trigliceridi (mg/dl)	52	30-95	Cloro (mEq/dl)	107	107-115
Urea (mg/dl)	20	15-55			





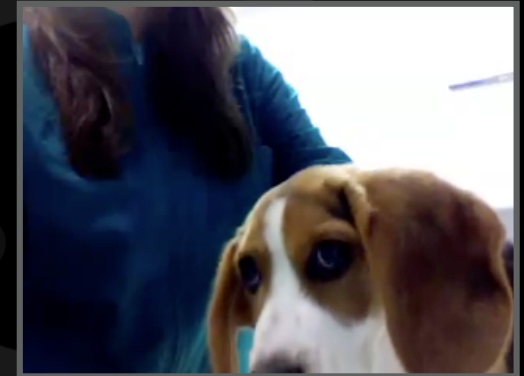Bacco, Beagle, MI, 4 months

Radiographic diagnoses:

Suspected abscess in the right thigh
 Not possible to define if the abdominal wall is intact

Next step

- Ultrasound



Bacco, MI, 4 months

Probe position in a different patient

7


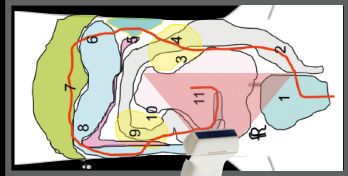
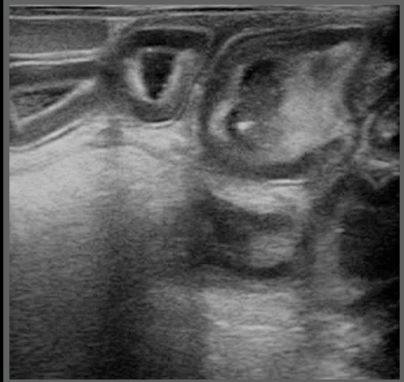
Bacco, MI, 4 months

Probe position in a different patient

6


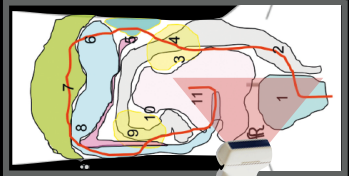

Bacco, MI, 4 months

Probe position in a different patient 11




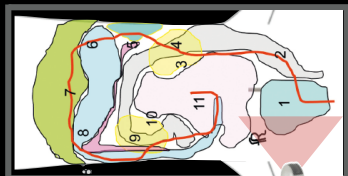

Bacco, MI, 4 months

Probe position in a different patient 11-1




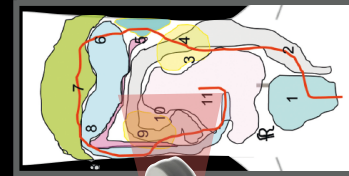

Bacco, MI, 4 months

Probe position in a different patient 1



Bacco, MI, 4 months

Probe position in a different patient 9



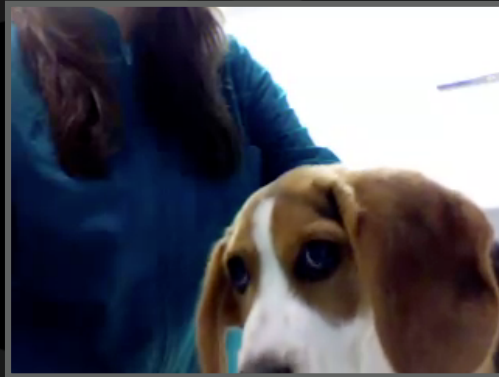Bacco, Beagle, MI, 4 months

Ultrasonographic diagnoses:

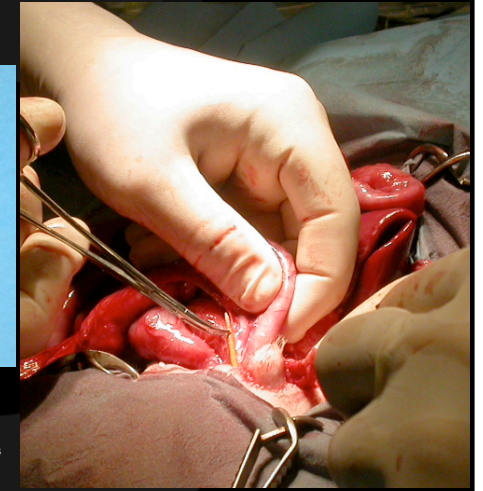
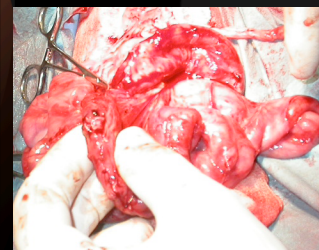
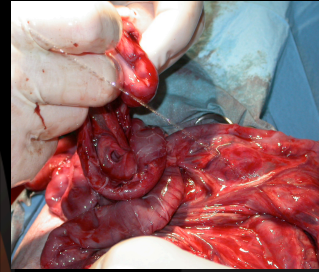
- Linear foreign body perforating the small intestine
- Possible abscess due to migration of the FB
- Possible right ureter obstruction due to inflammation

Next step

Laparotomy



Bacco, MI, 4 months



He recovered well,
discharged in three days

Conclusions

- Challenging FBs often benefit from ultrasound and radiology
- Don't undervalue radiology!



Thank you



Diagnostic Mindset

www.diagnosticmindset.com