

Corpi estranei gastrointestinali: lineari, metallici, ecogeni o solo gas?

Gliola Spattini
DVM, GP cert Cardio, CCRT, PhD, DECVDI



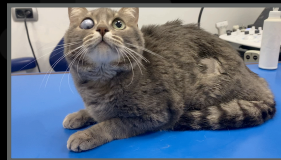Objectives

- Gastrointestinal FBs can be challenging
- Some more than others



Dori, DSH, FS, 2 years

- She had a viral infection when she was a kitten
- Chronically vomiting in the morning
- Resolved with dietary change
- Relapsed when the owner tried new food
- Not responding any more

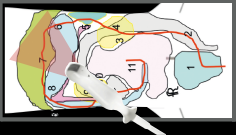
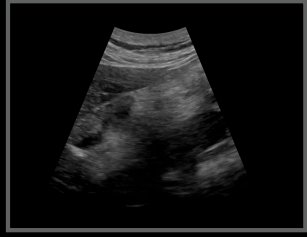
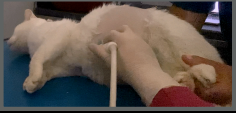


Dori, FS, 2 years



Probe position in a different patient

7-6

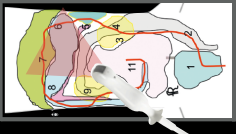
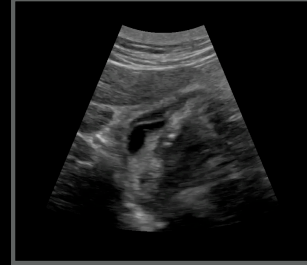
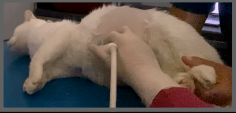


Dori, FS, 2 years



Probe position in a different patient

7-6

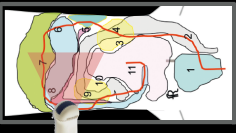
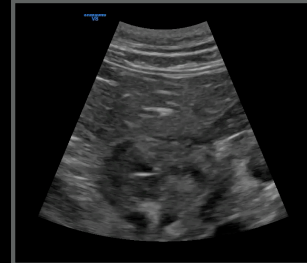
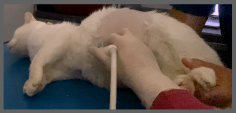


Dori, FS, 2 years



Probe position in a different patient

7-6

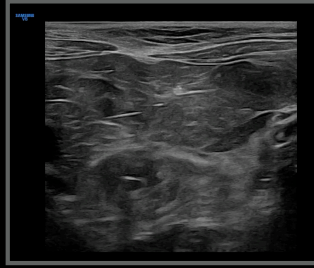
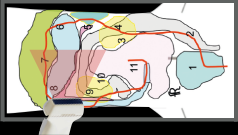



Dori, FS, 2 years



Probe position in a different patient

7-6

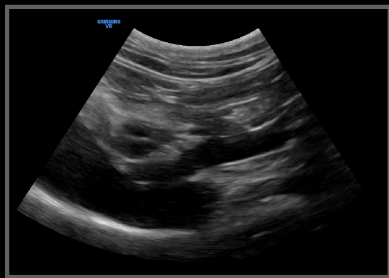
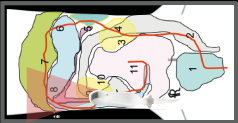
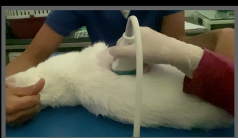

Dori, FS, 2 years



Probe position in a different patient

8'

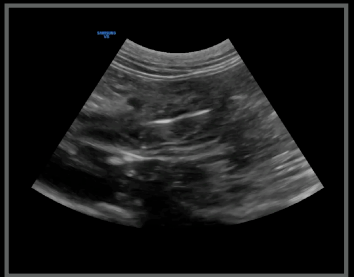
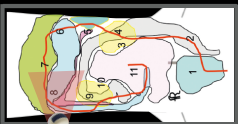
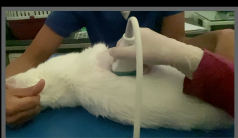
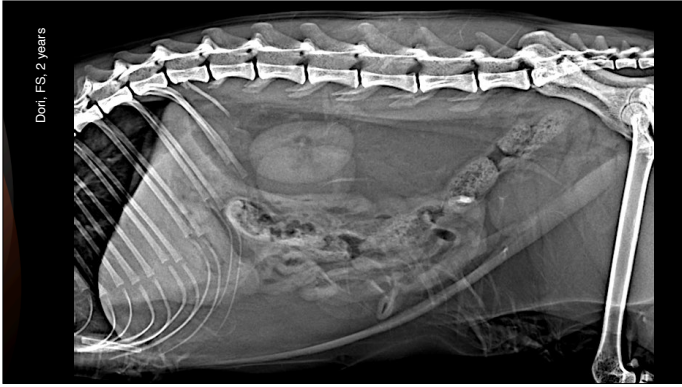
Dori, FS, 2 years

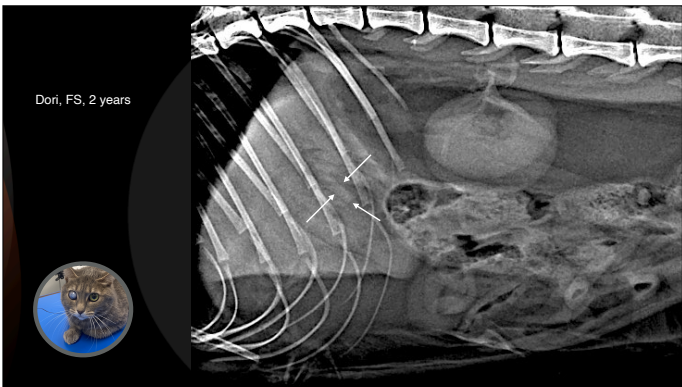

Probe position in a different patient

8'





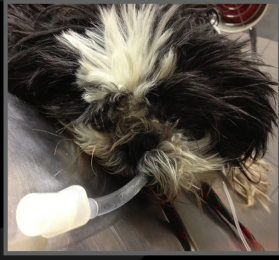

Dori, DSH, FS, 2 years

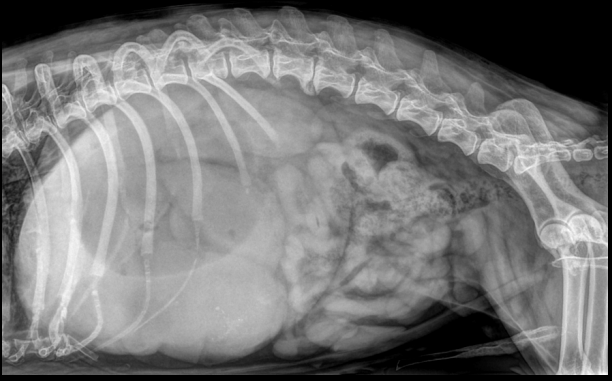- Dori went back to the referring veterinarian
- Three days later, an endoscopy was performed
- Several GE biopsies confirmed an underlying moderate lymphocytic-plasmacytic chronic gastro-enteritis
- The FB was removed

Romeo, Shitzu, MN, 13 years

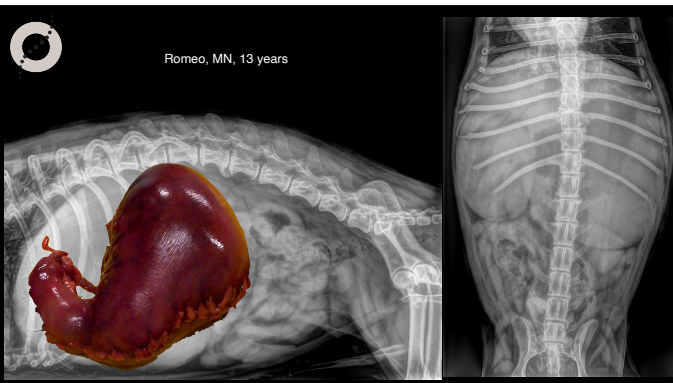
- History of chronic vomiting
- Progressively worse since last month



Romeo, MN, 13 years



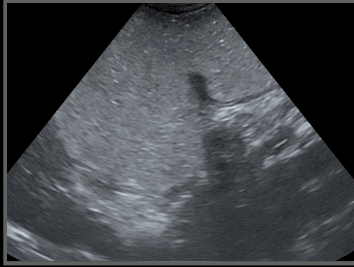
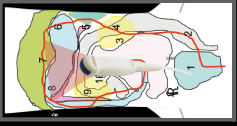
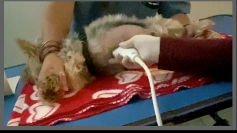Romeo, MN, 13 years



Romeo, MN, 13 years

Probe position in a different patient

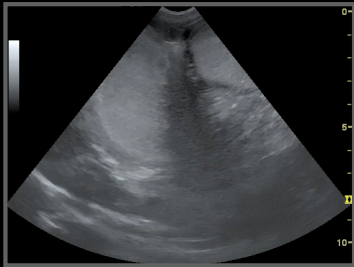
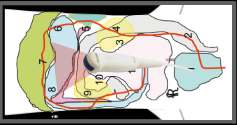
7



Romeo, MN, 13 years

Probe position in a different patient

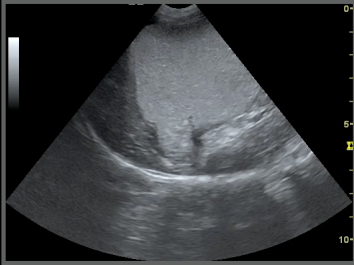
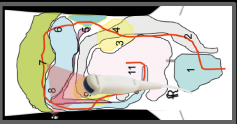7-8



Romeo, MN, 13 years

Probe position in a different patient

7-8



Bea, Dachshund, FS, 3 years

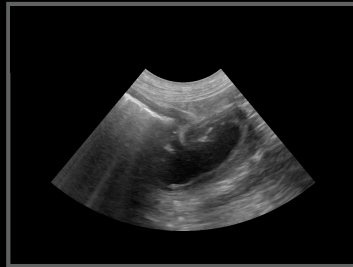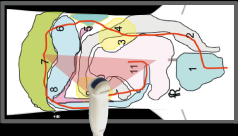
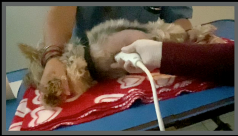- Trash scavenger
- She ate the cat's poo yesterday
- Vomiting and not eating



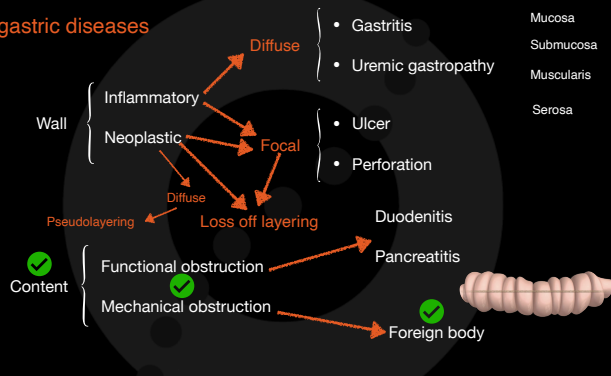
Bea, FS, 3 years

Probe position in a different patient

7-11

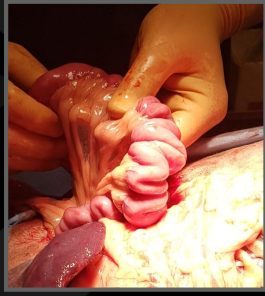

The gastric diseases



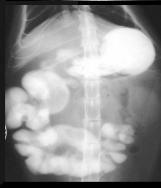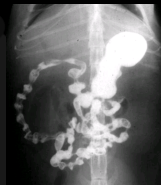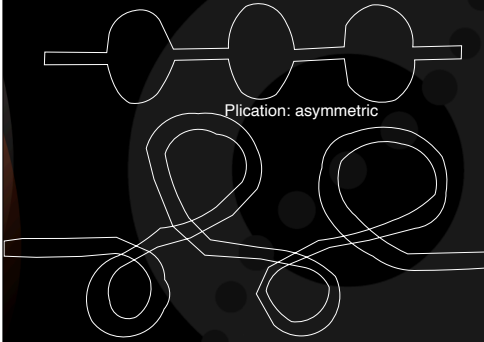
Bea, Dachshund, FS, 3 years

- Surgical removal of the linear FB



Corrugation: symmetric

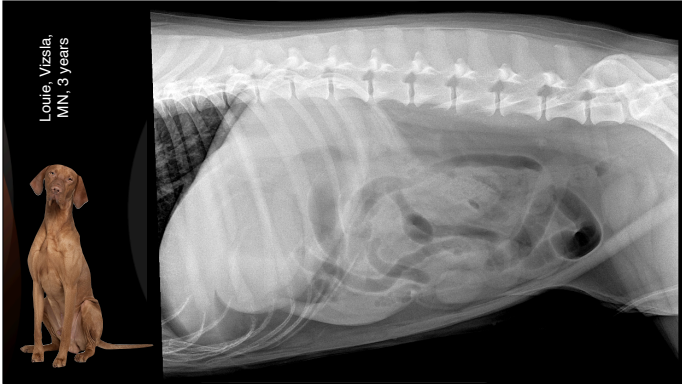
Plication: asymmetric

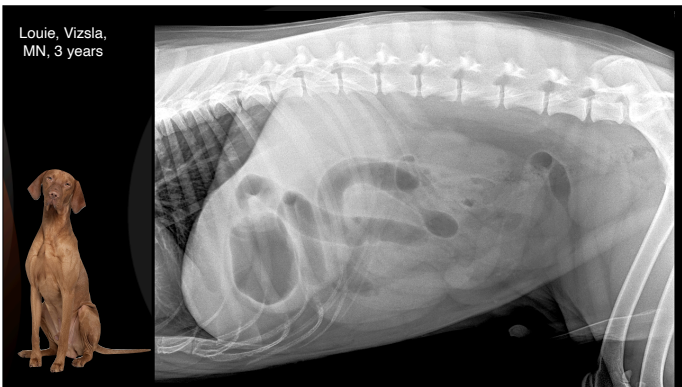


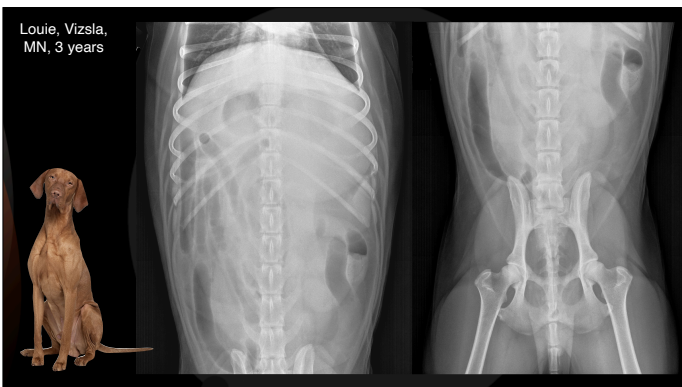Louie, Vizsla, MN, 3 years

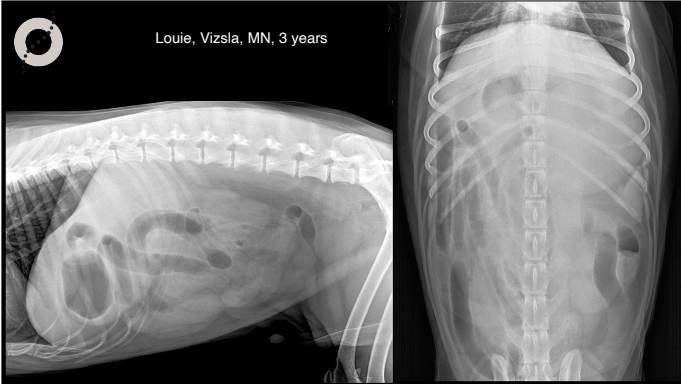- 24h history of vomiting
- Not responding to treatment
- On a strict diet for a sensitive stomach











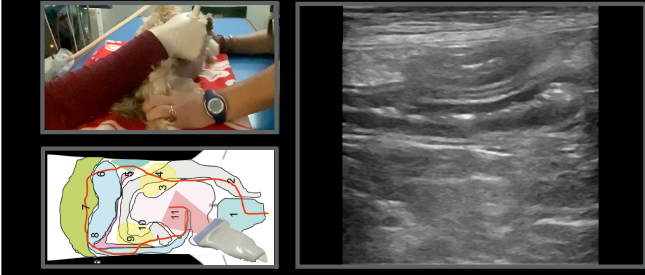
Your evaluation

- Is there a foreign body?
- Is there gastroenteritis?
- Is there a gastrointestinal occlusion?

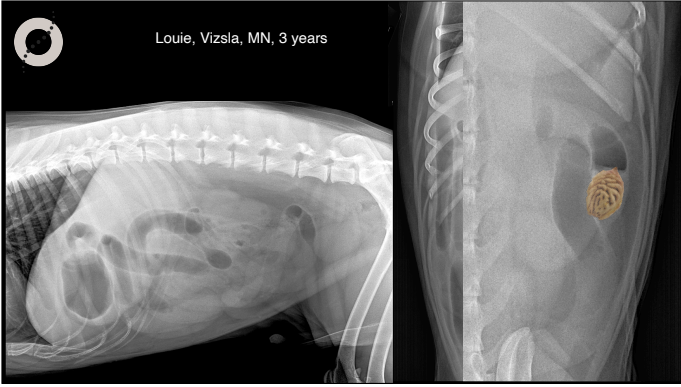

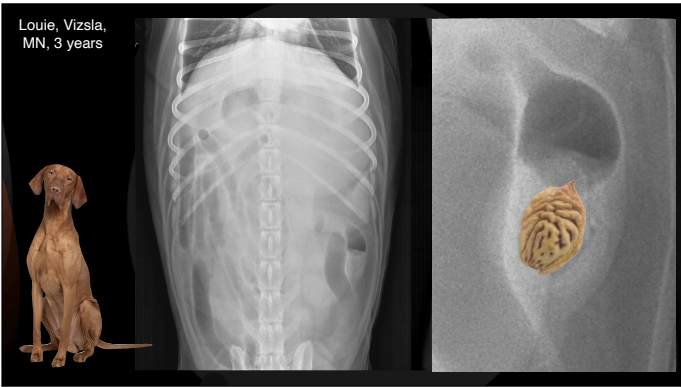
Louie, MN, 3 years

Probe position in another patient




11



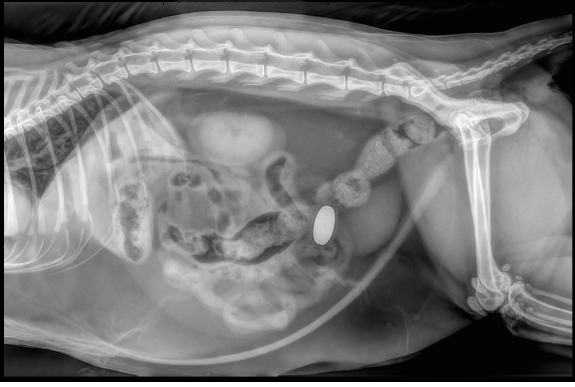

Key points

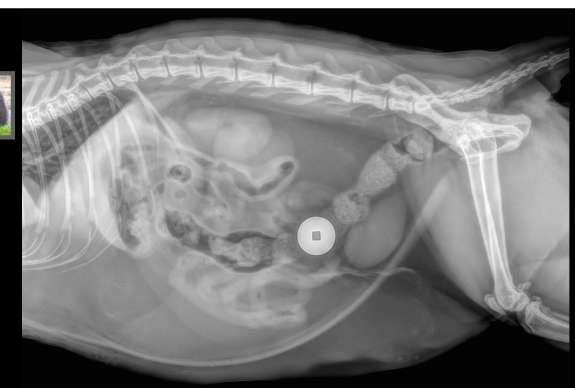
- Oval soft tissue structure
- Typical radiolucent curved lines
- Often only visible in one view



Tigro, MN,
6 years



Tigro, MN,
6 years



Tigro, MN, 6 years

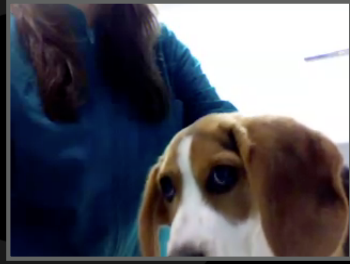

Bacco, Beagle, MI, 4 months

In the last two weeks decreased appetite

Lethargic

A swelling was noted by the owner in the right inguinal region



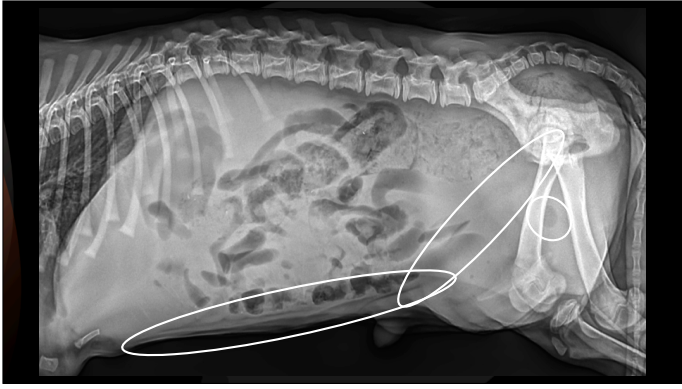
Bacco, Beagle, MI, 4 months

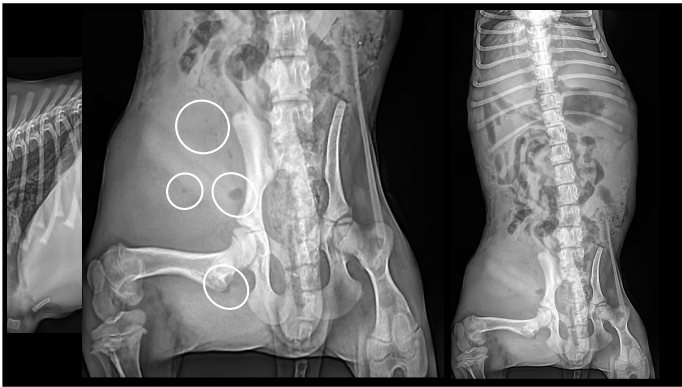
Blood work

BACCO, BEAGLE M, 4 MESI	PAZIENTE	RIFERIMENTO	BACCO	PAZIENTE	RIFERIMENTO
RBC	4.97	5.50 – 7.90	WBC (X 10 ³ /ul)	39900	6000-16000
Hb (g/dl)	10.1	12.0-18.0	Neutr. Banda (/ul)	11172	0-300
Hct (%)	29	37-55	Neutr. Segm (/ul)	17955	3600-14000
MCV (fl)	58	60-76	Linfociti (/ul)	5586	720-5750
MCH (pg)	20	20-25	Monociti (/ul)	5187	0-1400
MCHC (g/dl)	35	32-39	Morfologia	Linfociti attivati +	Neutr. Tossici ++
RDW (%)	17.6	10.0-16.0	BACCO	PAZIENTE	RIFER.
Morfologia	Codociti +		N PLT (X 1000/ul)	211	120-350
			MPV (fl)	9.7	8.0-12.3
			PCT (%)	0.206	0.120-0.300
			PDW (%)	23.9	10.0-27.0
			Stima a vetrino	Adeguate	

Bacco, Beagle, MI, 4 months

BACCO			BACCO		
ALT (u/L)	11	15-50	Crea (mg/dl)	0.30	0.75-1.30
ALP (u/L)	157	20-105	Glu (mg/dl)	75	60-100
PROT. TOT.	6.4	5.5-7.7	Calcio (mg/dl)	9.3	8.0-12.0
ALB (mg/dl)	2.5	2.6-3.8	Fosforo (mg/dl)	6.9	2.1-6.2
GLOB (mg/dl)	3.9	2.6-4.5	Sodio (mEq/dl)	139	140-150
Rapp. A/G	0.6	0.7-1.2	Potassio (mEq/dl)	3.2	3.9-4.8
Colesterolo (mg/dl)	269	120-255	Rapporto Na/K	43	> 30
Trigliceridi (mg/dl)	52	30-95	Cloro (mEq/dl)	107	107-115
Urea (mg/dl)	20	15-55			





Bacco, Beagle, MI, 4 months

Radiographic diagnoses:

Suspected abscess in the right thigh
Not possible to define if the abdominal wall is intact

Next step

- Ultrasound

