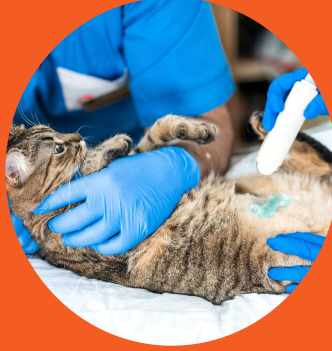

“L'ombra del dubbio: artefatti acustici, pseudomasse e trabocchetti”

Giulia Spattini
DVM, GP Cardio, CCRT, PhD, DECVI



Objectives

- All the masses are neoplasias?
- Challenging cases



Horos, DSH, MN, 13 years

- Two days history of head tilt
- Anorexia
- One episode of vomiting

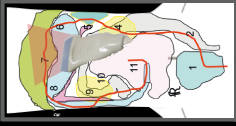
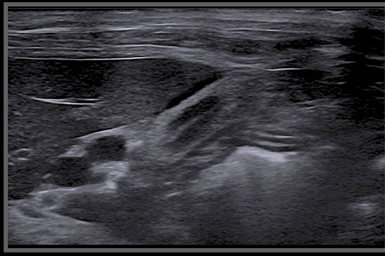
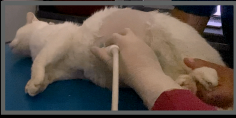




Horos, MN, 13 years

Probe position in a different patient

7-6

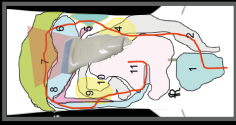
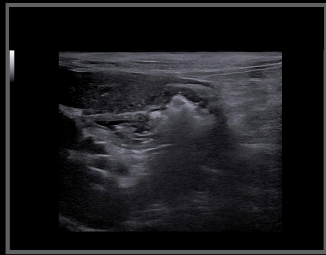
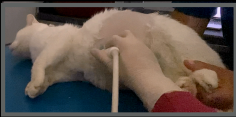



Horos, MN, 13 years

Probe position in a different patient

7-8

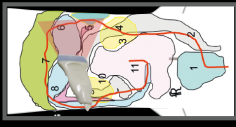
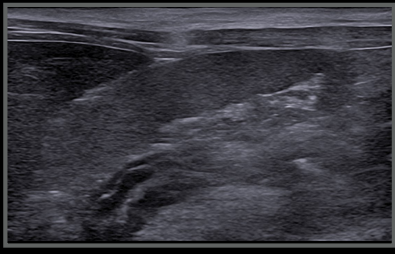
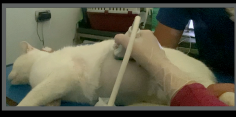



Horos, MN, 13 years

Probe position in a different patient

6 - 5

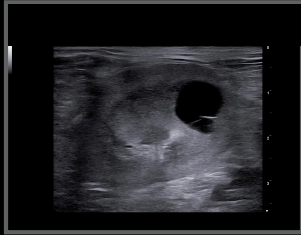
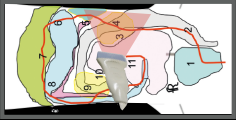
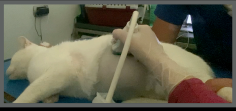


Horos, MN, 13 years

Probe position in a different patient

4

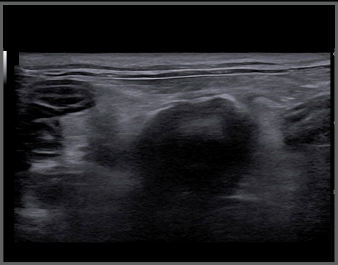
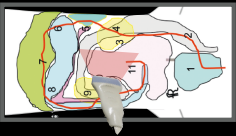
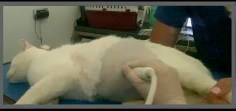



Puffetta, FS, 11 years

Probe position in a different patient

7-11

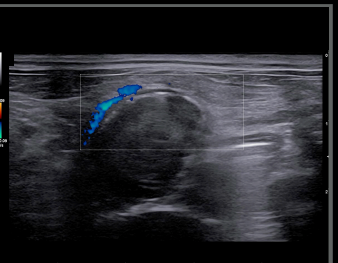
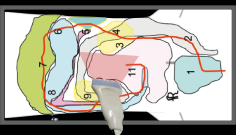



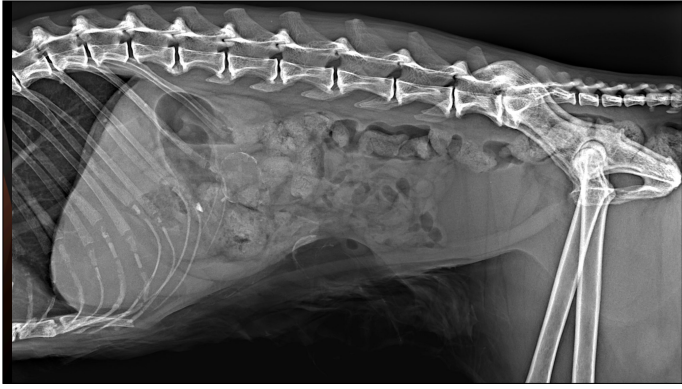

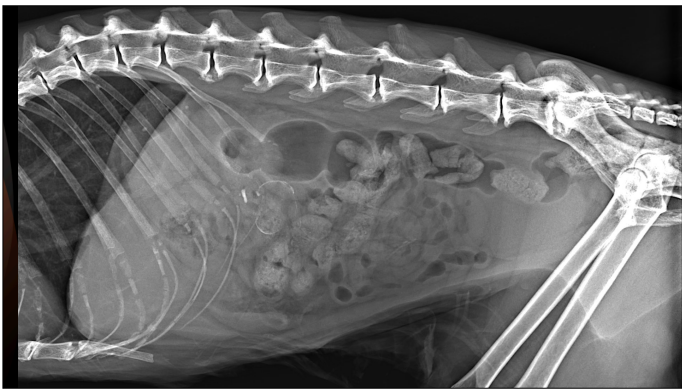
Puffetta, FS, 11 years

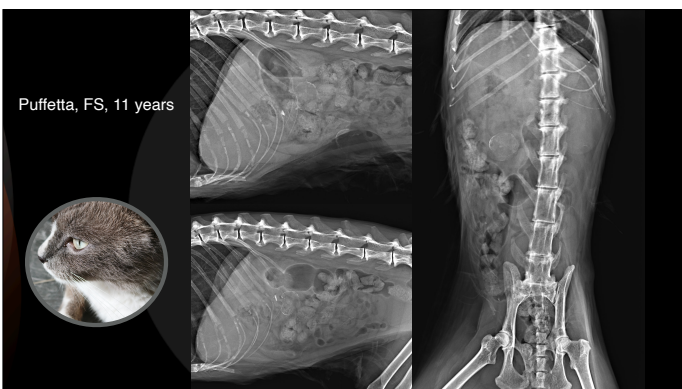
Probe position in a different patient

7-11

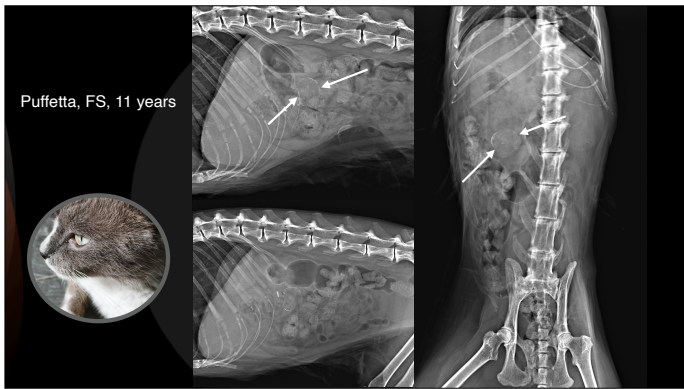


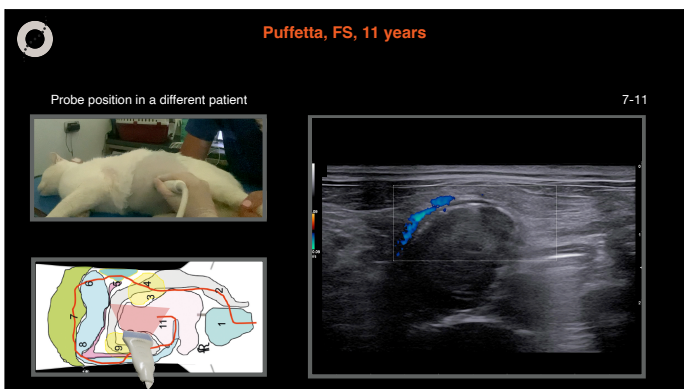






Your evaluation

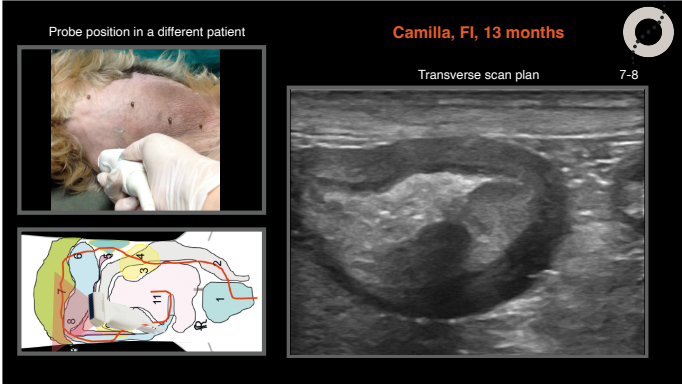




Probe position in a different patient

Camilla, FI, 13 months


Transverse scan plan 7-8



The slide shows a clinical photograph of a dog's head with an ultrasound probe on the neck, a schematic diagram of the dog's head and neck with colored regions and probe placement, and a corresponding transverse ultrasound scan of the neck area.

Camilla, French Bulldog, FI, 3 years

- Worsening of the GE clinical signs
- Surgical GE biopsy and pyloroplasty performed
- Histology confirmed an underlying chronic gastritis



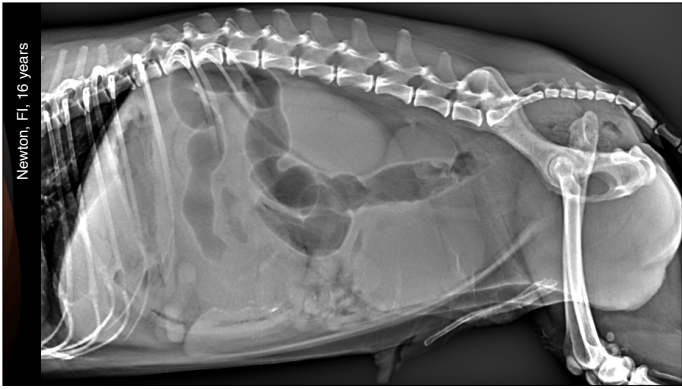
The slide features two photographs of surgical specimens, likely the stomach and pylorus, showing the results of a biopsy and pyloroplasty procedure.

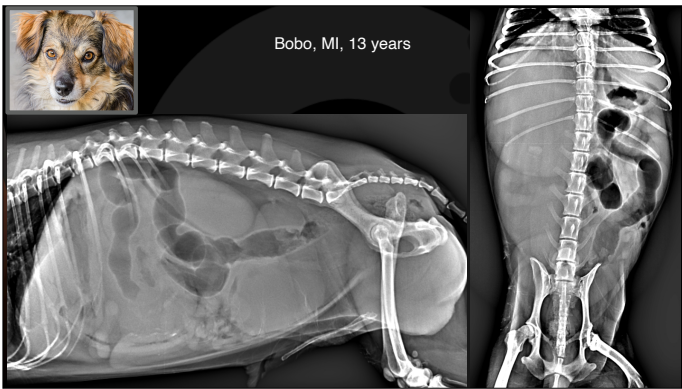
Bobo, Mongrel, MI, 13 years

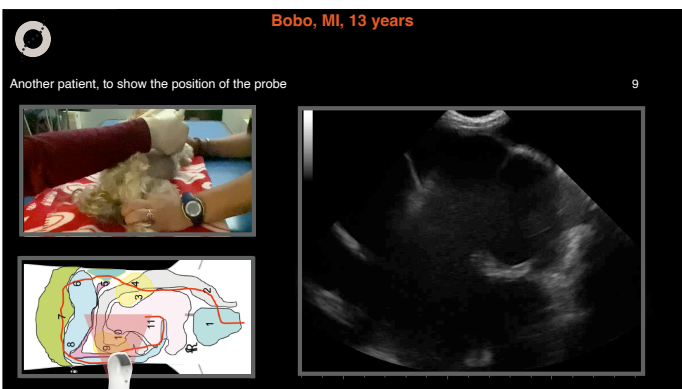
- Progressively distended abdomen for the last weeks
- Acute abdomen



The slide includes a photograph of a dog's face, identified as Bobo, a 13-year-old mongrel with a mix of brown, tan, and white fur.







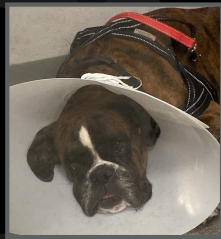Simba, Corso, MN, 9 years

- Recovered in three days
- The free fluid was blood, no urine
- Doing fine one month later



Laika, Boxer, FS, 7 years

- Hit by a car
- Severe hematoma in the caudal abdomen
- Distended abdomen

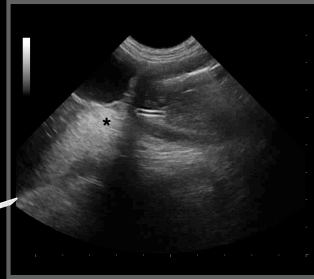
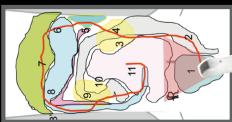
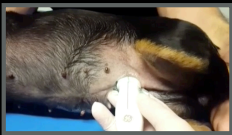Laika, FS, 4 years

Is the UB ruptured?

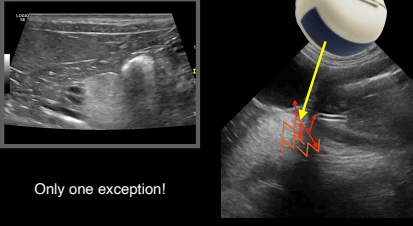

Why is the peritoneum hyperechoic? 1

Probe position



Scattering artifact

If scattering artifact is present then peritonitis and inflammation is there!



Only one exception!


Laika, Boxer, FS, 7 years

- Ruptured UB, confirmed with positive contrast
- Recovered after surgery



Conclusions

- With a systematic approach even difficult cases can be diagnosed
- Basic radiographic and ultrasonographic physics is needed to increase diagnostic accuracy



Thank you



Diagnostic Mindset

www.diagnosticmindset.com
