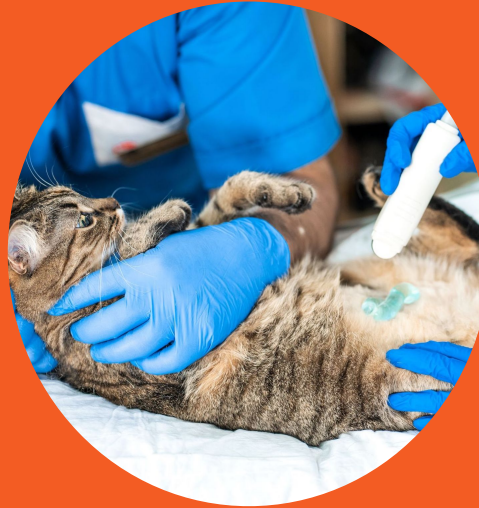

“L'ombra del dubbio: artefatti acustici, pseudomasse e trabocchetti”

Giulio Spattini
DVM, GP Cardio, CCRT, PhD, DECVDI



Diagnostic Mindset



Objectives

- All the masses are neoplasias?
- Challenging cases



Horos, DSH, MN, 13 years

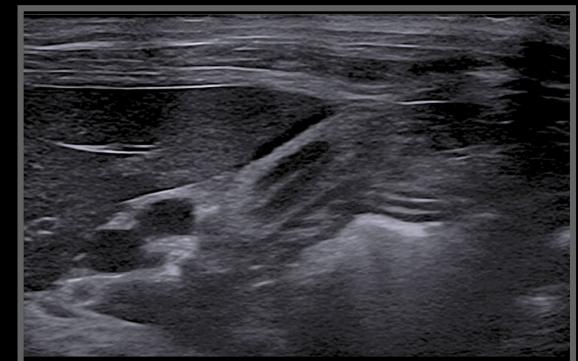
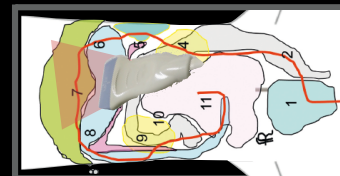
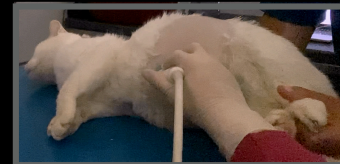- Two days history of head tilt
- Anorexia
- One episode of vomiting



Horos, MN, 13 years

Probe position in a different patient

7-6

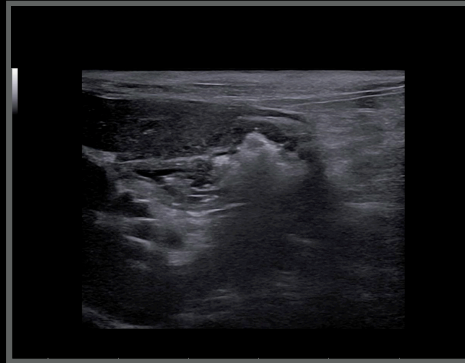
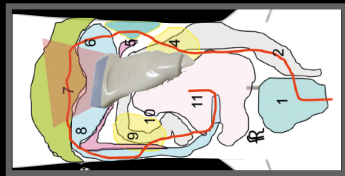
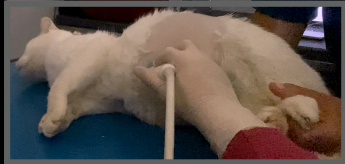



Horos, MN, 13 years

Probe position in a different patient

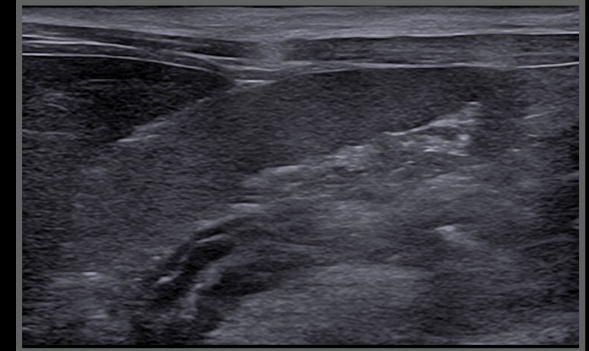
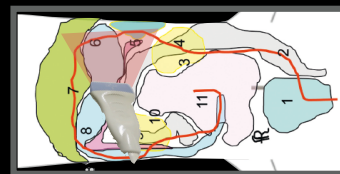
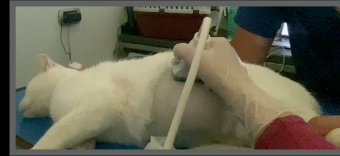7-8



Horos, MN, 13 years

Probe position in a different patient

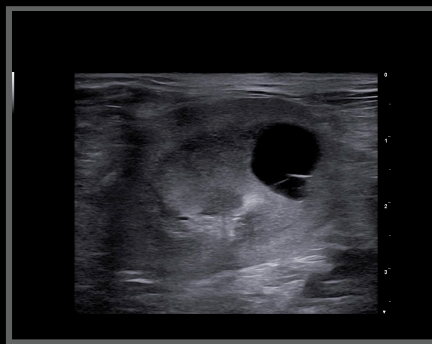
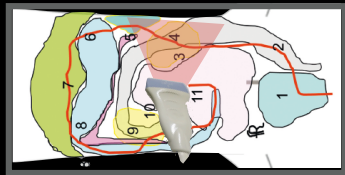
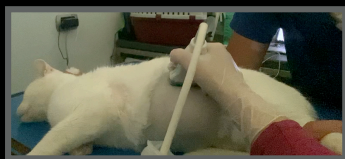6 - 5



Horos, MN, 13 years

Probe position in a different patient

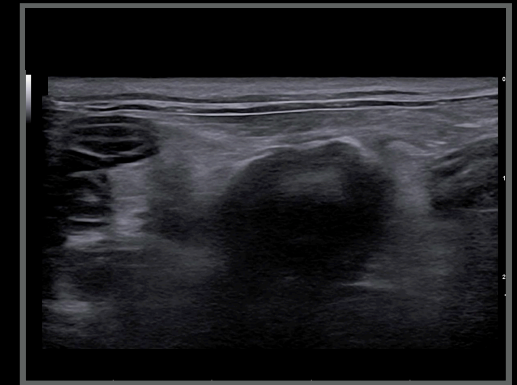
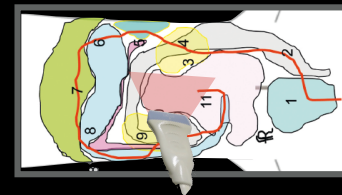
4



Puffetta, FS, 11 years

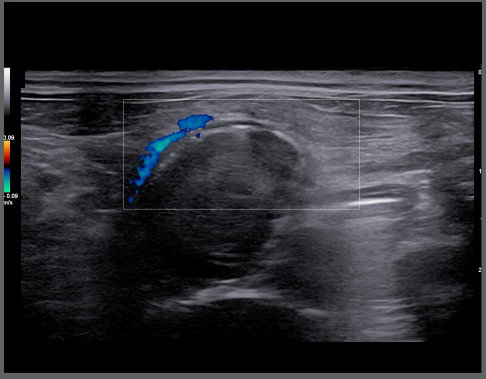
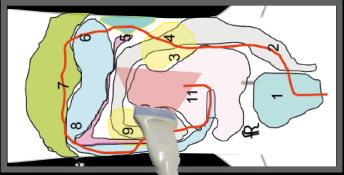
Probe position in a different patient

7-11



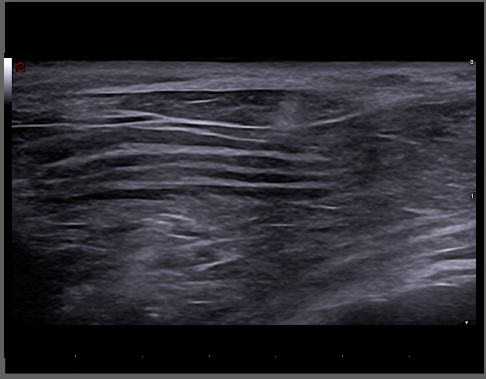
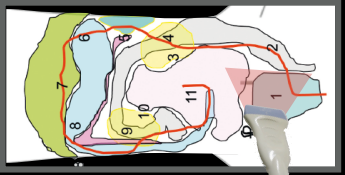
Puffetta, FS, 11 years

Probe position in a different patient 7-11

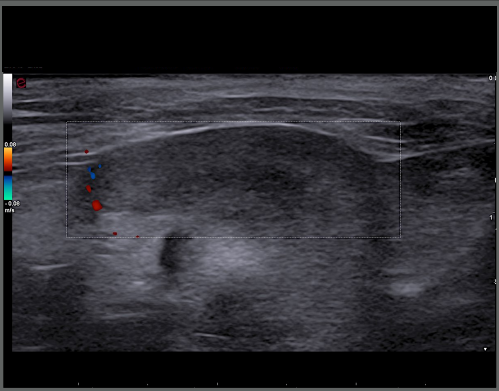
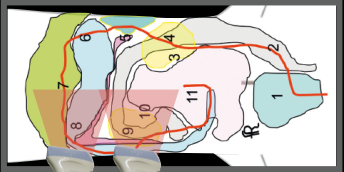
Puffetta, FS, 11 years

Probe position in a different patient 7-11


Puffetta, FS, 11 years

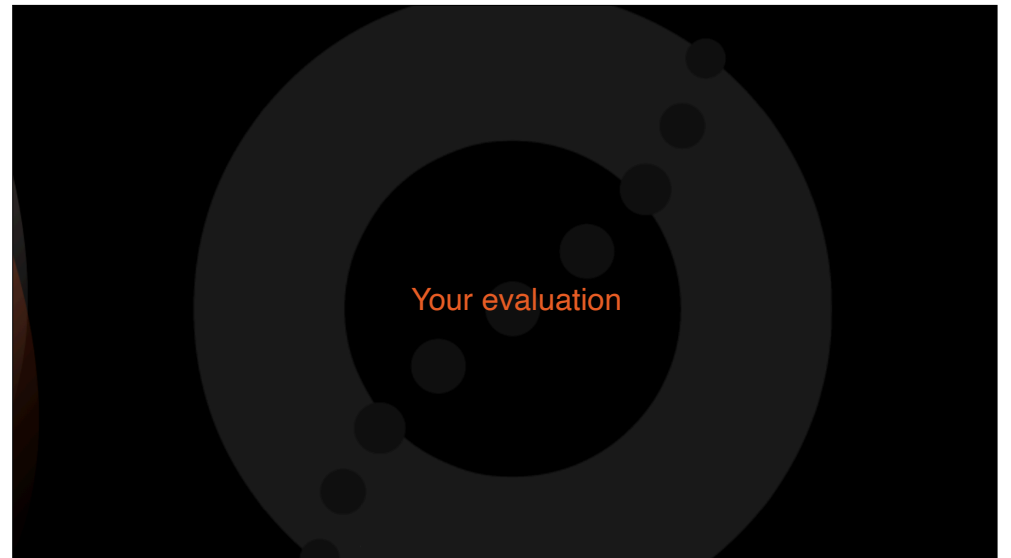
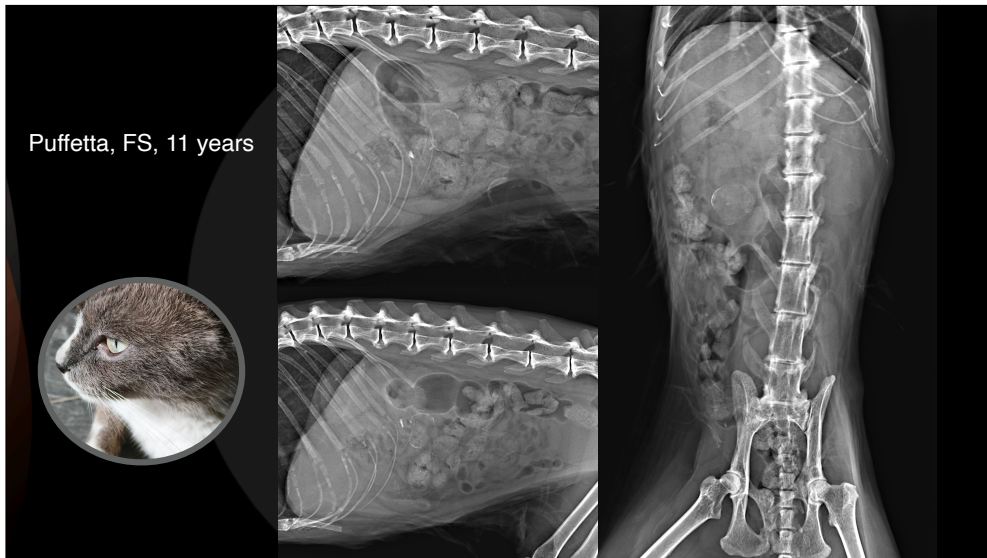
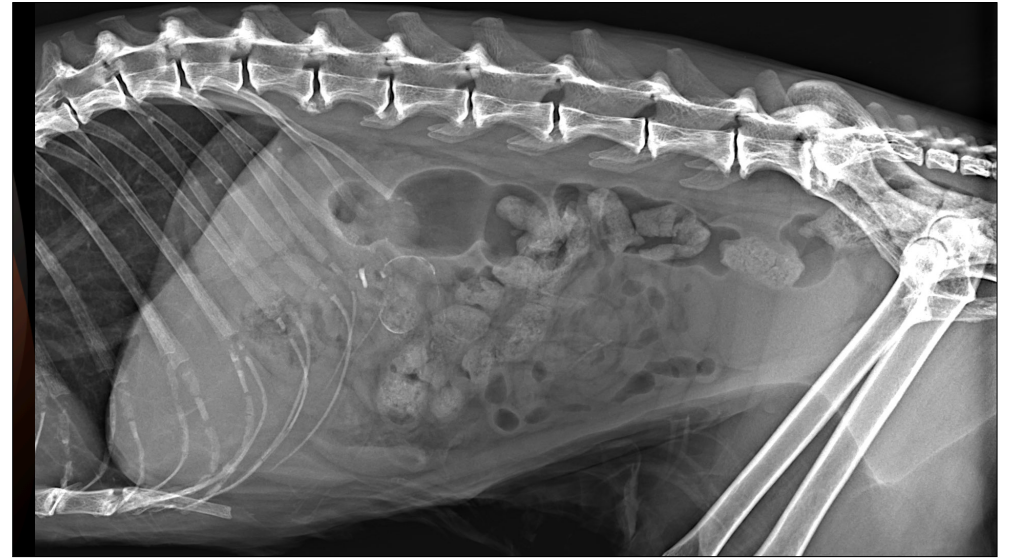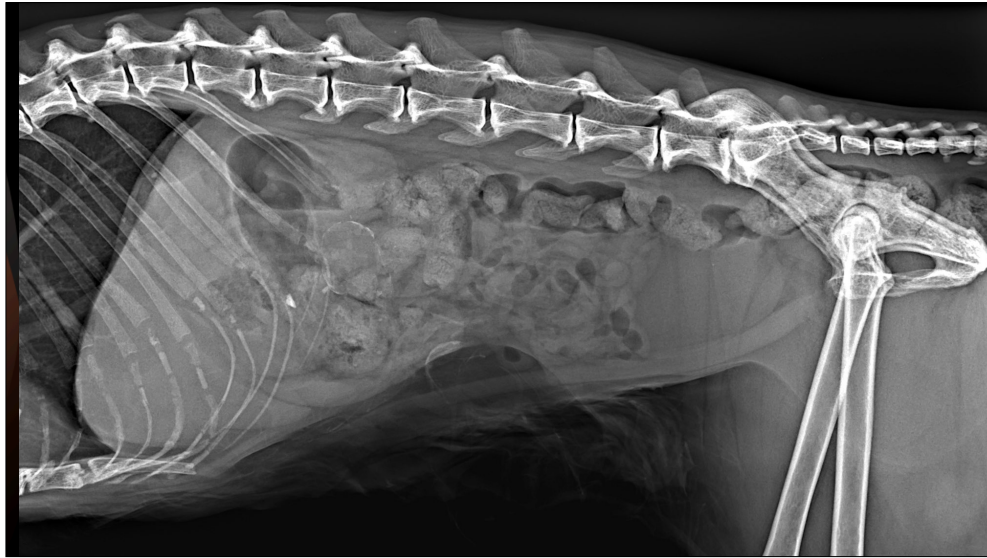
8'

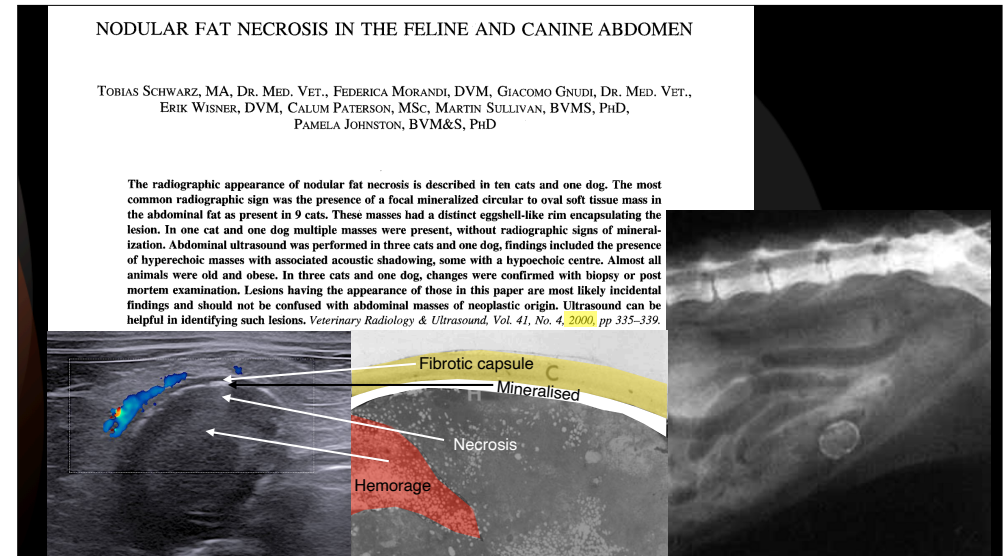
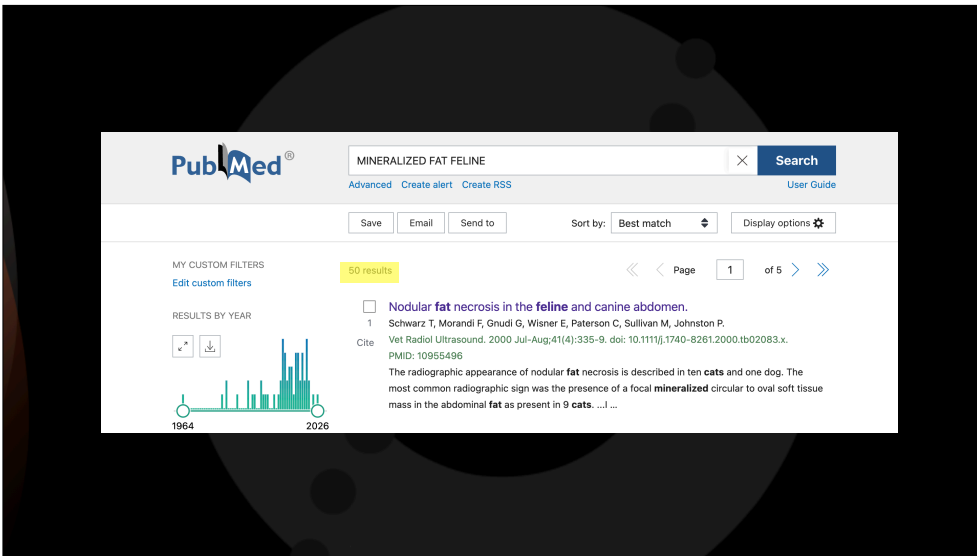
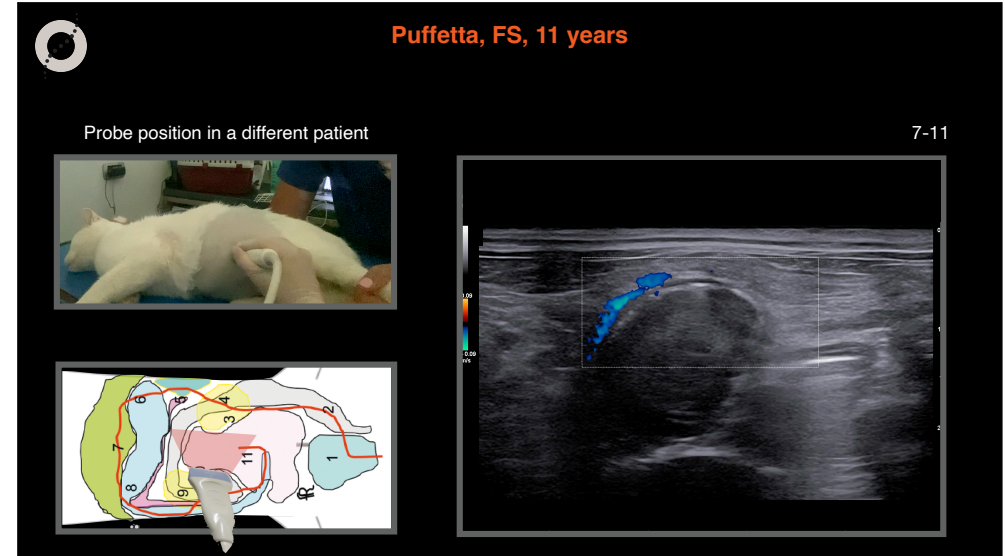
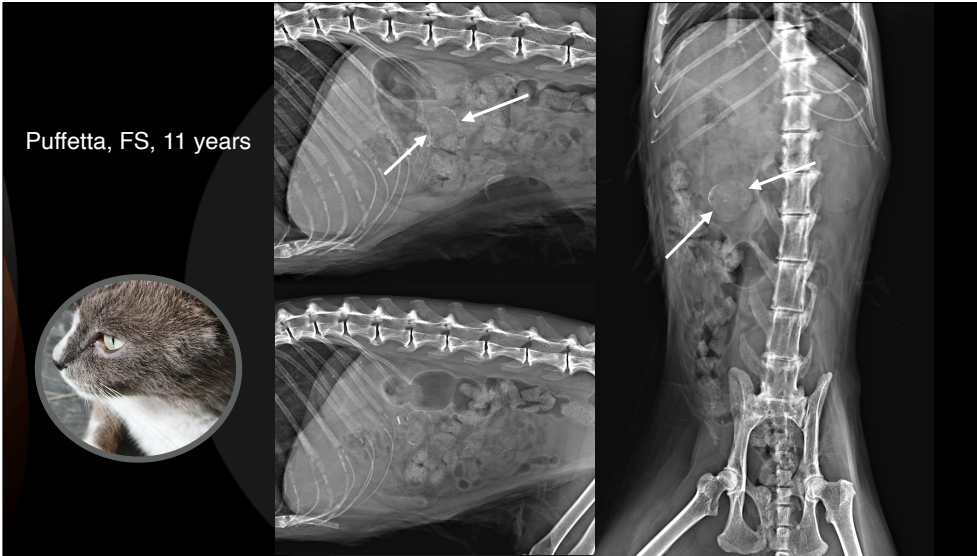



Your evaluation

- What is your most likely differential diagnosis?





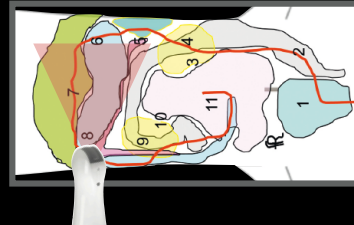
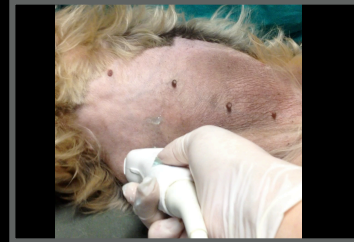

Camilla, French Bulldog, FI, 3 months

- Projectile vomiting for two days
- Anorexia
- Depression



Probe position in a different patient

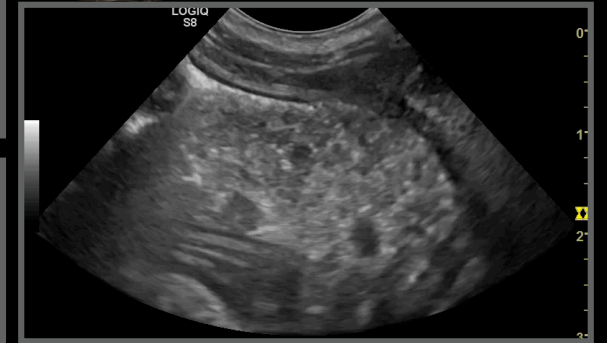

Camilla, FI, 3 months

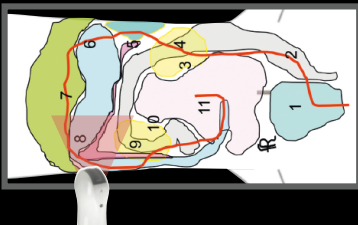
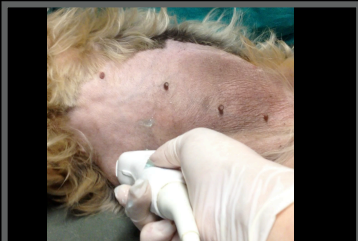

Transverse scan plan

7-8



Probe position in a different patient

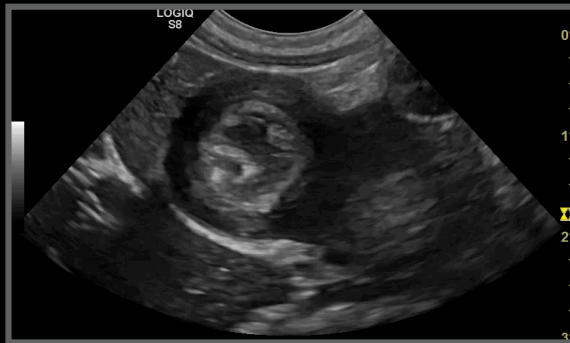

Camilla, FI, 3 months

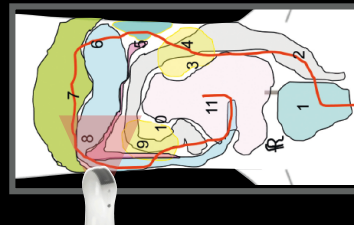
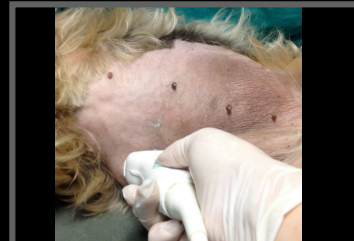

Transverse scan plan

8-8'



Probe position in a different patient

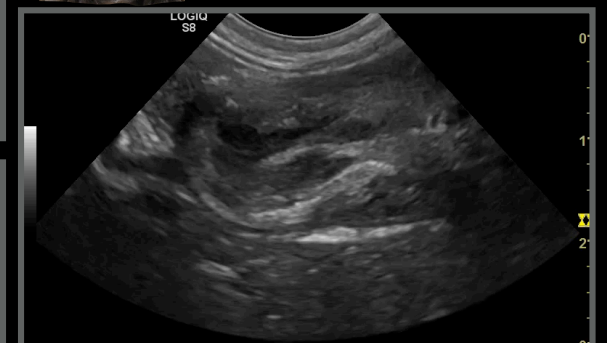


Camilla, FI, 3 months




Transverse scan plan


8-8'




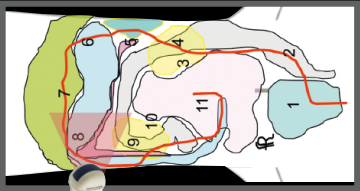
Probe position in a different patient



Camilla, FI, 3 months



Longitudinal scan plan 8-8°





Your evaluation

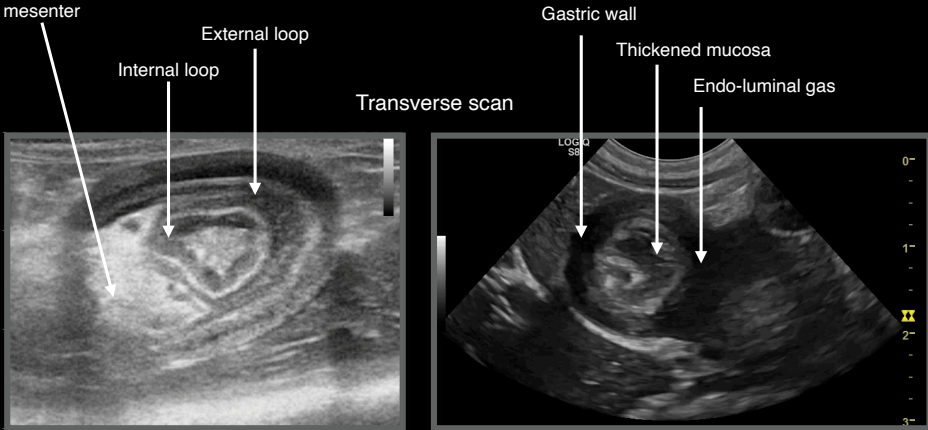
- Is there an intestinal foreign body?
- Is there intussusception?
- Is there acute gastroenteritis?



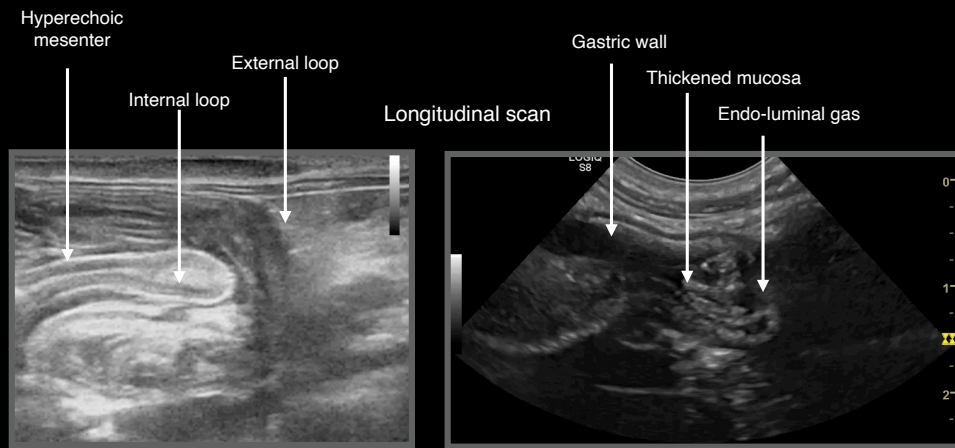
Intussusception



Intussusception VS pyloric hypertrophy



Intussusception VS pyloric hypertrophy



Camilla, French Bulldog, FI, 3 months

Ultrasonographic diagnoses:

- Reduced pyloric-duodenal passage
- Thickened gastric mucosa
- Prominent pyloric muscular layer



How to arrive to Conclusions:

- PE examination
- Blood works
- Ultrasonographic findings
- Literature



PubMed®

pyloric hypertrophy dog

Advanced Create alert Create RSS User Guide

Save Email Send to Sort by: Best match Display options

MY CUSTOM FILTERS Edit custom filters

25 results

RESULTS BY YEAR

1966 2026

PUBLICATION DATE

1 year 5 years

1 Acquired antral pyloric hypertrophy in the dog.

Walter MC, Matthiesen DT.

Cite Vet Clin North Am Small Anim Pract. 1993 May;23(3):547-54. doi: 10.1016/s0195-5616(93)50304-2. PMID: 8503159

Acquired antral pyloric hypertrophy is one of the most common causes of pyloric obstruction in the small (10 kg) mature or old dog. ...Definitive diagnosis is made by exploratory laparotomy and histologic examination of excised tissues. Most dogs ...

2 Pyloric stenosis in the dog caused by hypertrophy of the circular muscle of the pylorus.

Walsh MH, Quigley PJ.

Cite Vet Rec. 1966 Jan 1;78(1):13-5. doi: 10.1136/vr.78.1.13. PMID: 5948094 No abstract available.

PubMed® gastroesophageal intussusception dog Search

Advanced Create alert Create RSS User Guide

Save Email Send to Sort by: Best match Display options

MY CUSTOM FILTERS Edit custom filters

RESULTS BY YEAR

PUBLICATION DATE

1 year
 5 years
 10 years
 Custom Range

TEXT AVAILABILITY

Abstract
 Free full text
 Full text

28 results Page 1 of 3

Gastroesophageal intussusception.
 1 Morris EL, Turnwald GH.
 Cite J Am Vet Med Assoc. 1980 Feb 15;176(4):361-2.
 PMID: 7358555 Free article. No abstract available.

Gastroesophageal intussusception in a 50-day-old German shepherd dog.
 2 Torad FA, Hassan EA.
 Cite Top Companion Anim Med. 2015 Mar;30(1):22-4. doi: 10.1053/j.tcam.2015.02.004. Epub 2015 Mar 4.
 PMID: 26041593
 We describe the clinical, radiographic, ultrasonographic, and gross pathologic examinations of a 50-day-old German Shepherd dog with gastroesophageal intussusception associated with esophageal dilatation. The dog was brought to the clinic 10 days after ...

Gastroesophageal Intussusception Associated with Pneumonectomy in a Dog.
 3 Weekley LB, Read R, Wu E, Takeda S, Hsia CC, Johnson RL.
 Cite Contemp Top Lab Anim Sci. 1997 Jan;36(1):91-93.
 PMID: 12456195
 Gastroesophageal intussusception is a rare condition in dogs. We report a gastroesophageal intussusception in an adult dog which had been subjected to unilateral pneumonectomy as a pup. ...At 15 months after surgery, the dog was fo ...

SMALL ANIMALS

CLINICAL REVIEW AND CASE REPORT

pyloric stenosis bulldog Search

Advanced Create alert Create RSS User Guide

Ultrasonographic and surgical findings of a gastric hyperplastic polyp resulting in pyloric obstruction in an 11-week-old French Bulldog

S Kuan,* K Hoffmann^a and P Tisdall^{a,b} *Aust Vet J* 2009;87:253–255

Camilla, French Bulldog, FI, 3 months

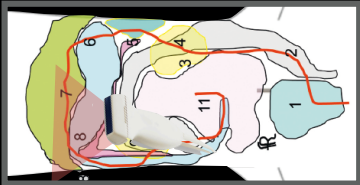
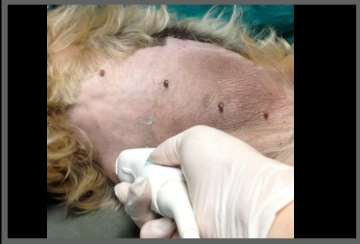Conclusions:

- Partial pyloric stenosis due to pyloric mucosal hypertrophy
- The patient responded very well to acute gastritis treatment with a reduction of the stenosis

Camilla, French Bulldog, FI, 13 months

- Control for chronic GE disease
- She is doing fine but vomits/regurgitates often after drinking

Probe position in a different patient

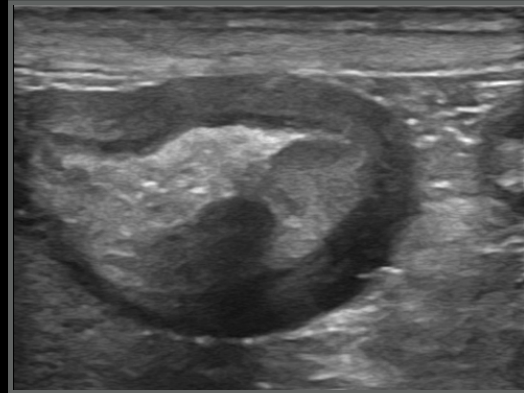


Camilla, FI, 13 months



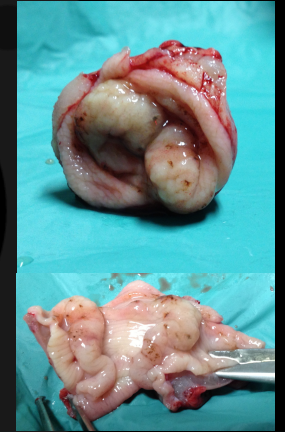Transverse scan plan

7-8



Camilla, French Bulldog, FI, 3 years

- Worsening of the GE clinical signs
- Surgical GE biopsy and pyloroplasty performed
- Histology confirmed an underlying chronic gastritis

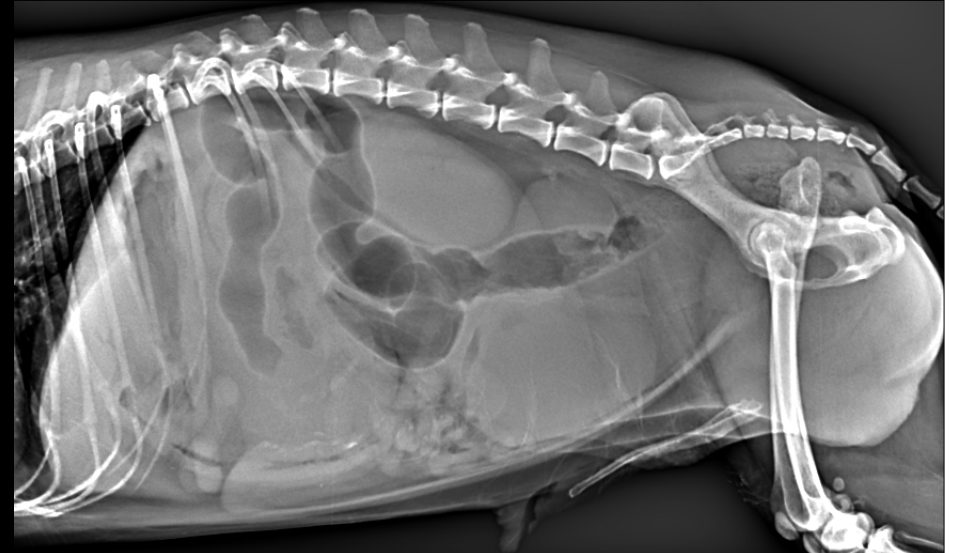

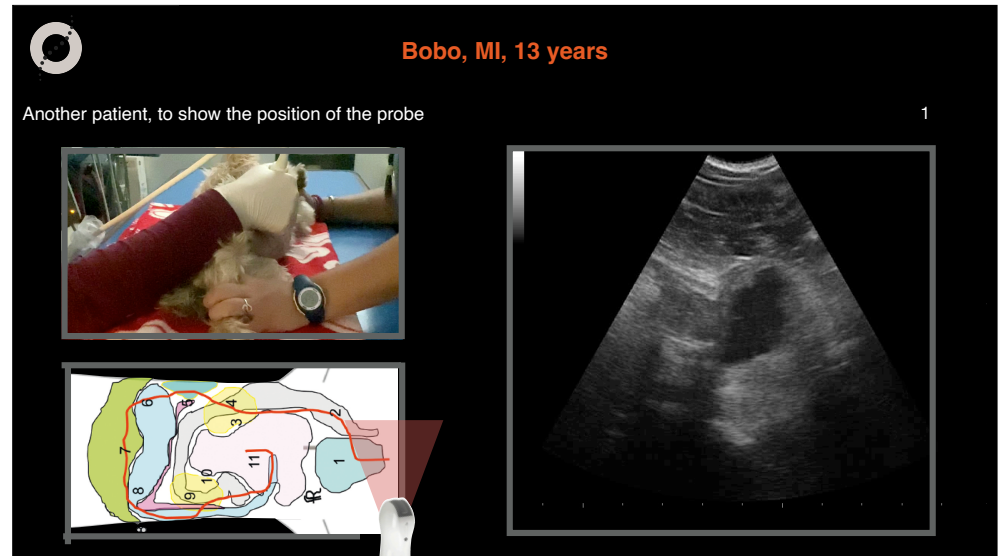
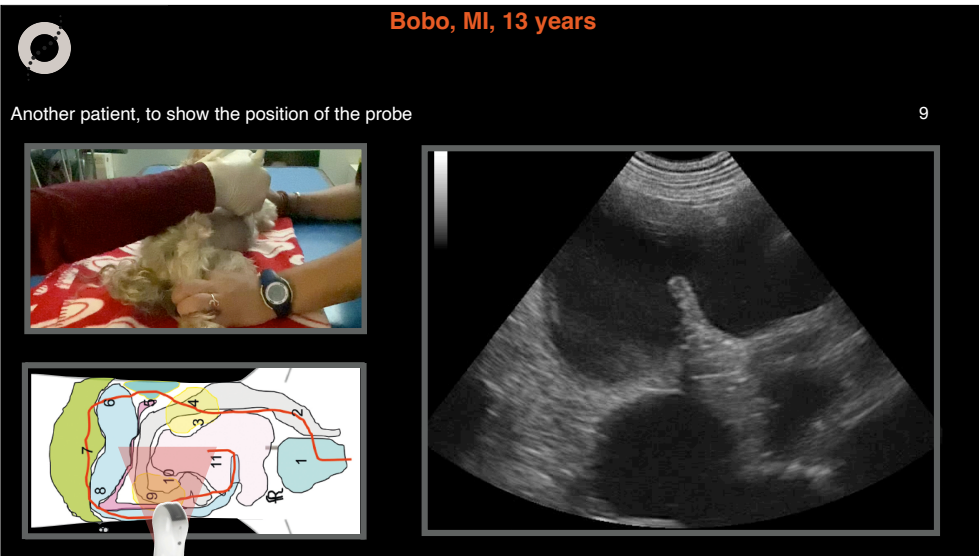
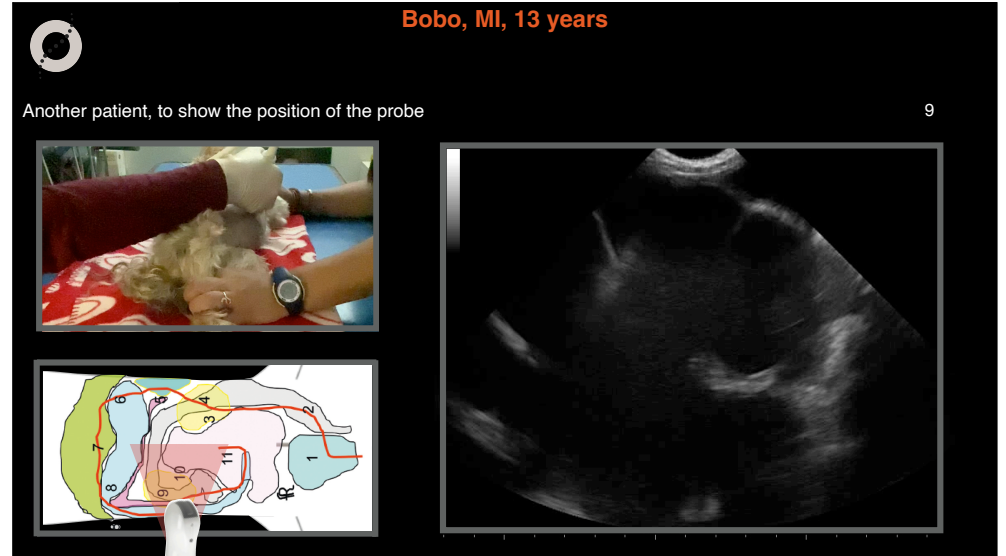
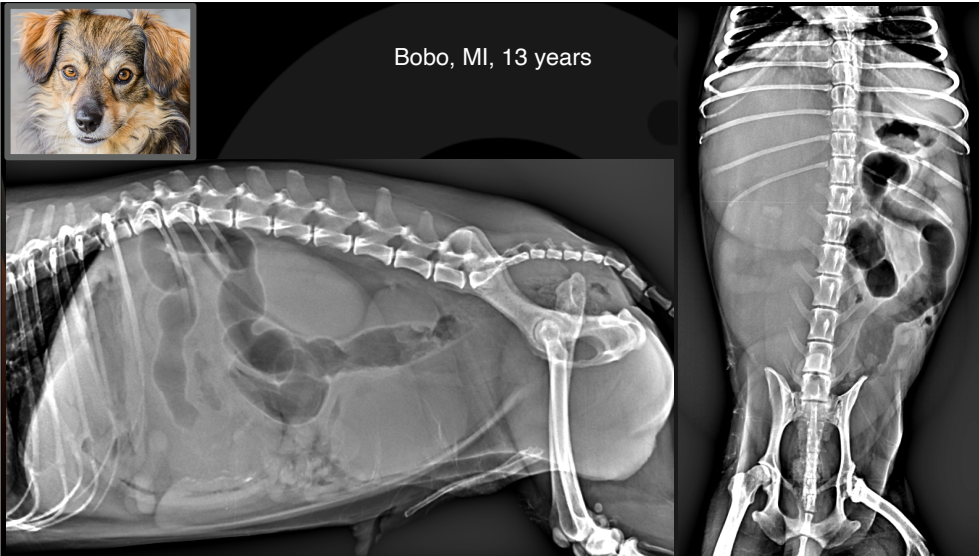
Bobo, Mongrel, MI, 13 years

- Progressively distended abdomen for the last weeks
- Acute abdomen



Newton, FI, 16 years



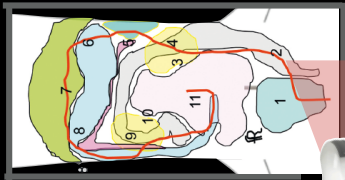
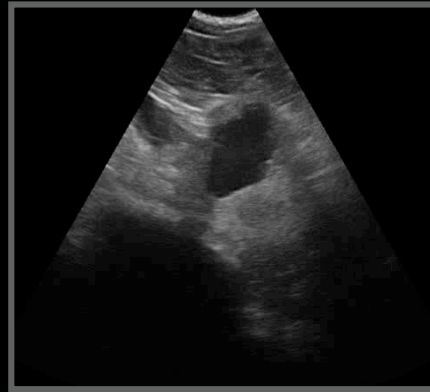
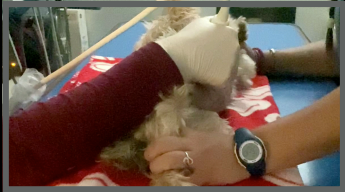


Bobo, MI, 13 years

Another patient, to show the position of the probe

1



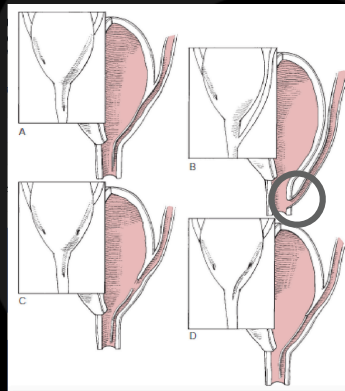
Bobo, Mongrel, MI, 13 years

Ultrasonographic diagnoses:

- Severe right sided hydronephrosis
- Severely over distended right ureter
- Prostatic termination of the right ureter



Ectopic ureters

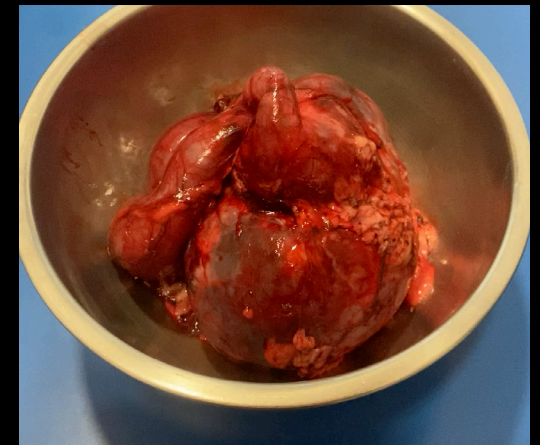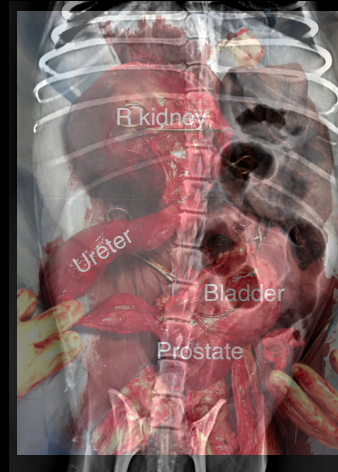


CT

Endoscopy

Rad + contr

Bobo, Mongrel, MI, 13 years



Simba, Corso, MN, 9 years

- Hip by a car
- Severe bruising and hematoma in the caudal abdomen

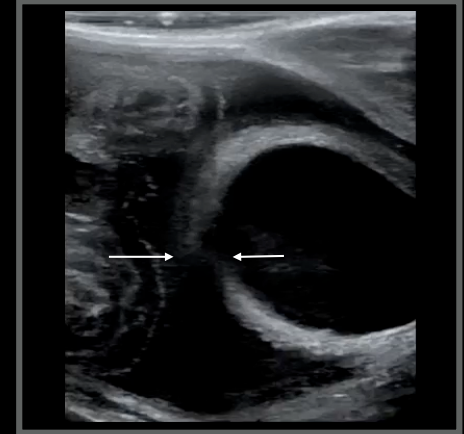
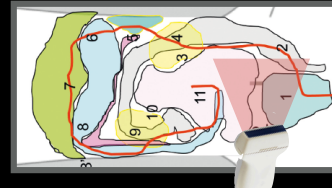
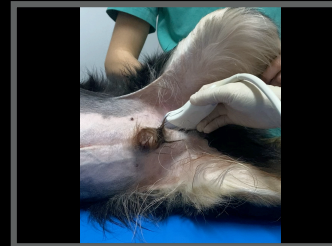


Simba, MN, 9 years

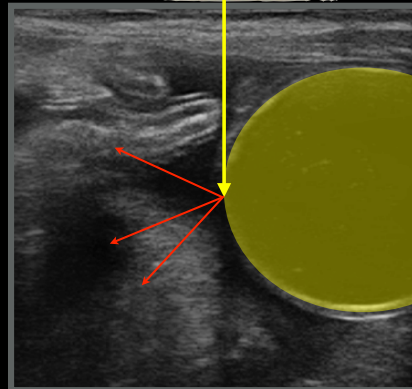
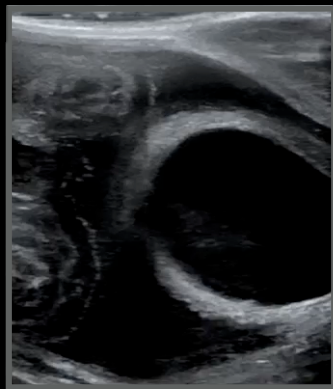
Probe position

Is the UB ruptured?

1



Refraction artifact



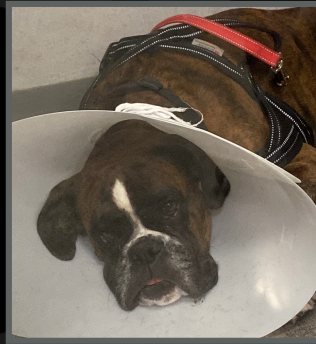Simba, Corso, MN, 9 years

- Recovered in three days
- The free fluid was blood, no urine
- Doing fine one month later



Laika, Boxer, FS, 7 years

- Hit by a car
- Severe hematoma in the caudal abdomen
- Distended abdomen

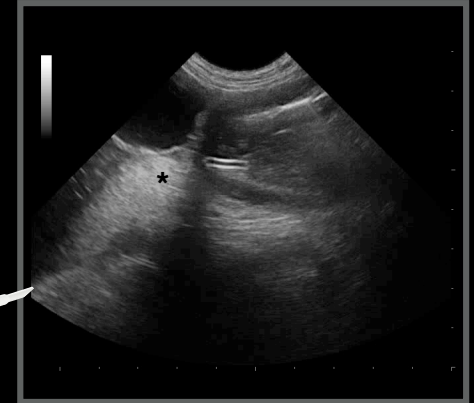
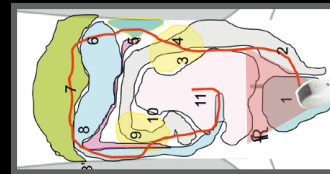
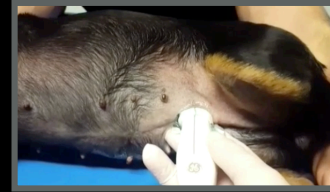Laika, FS, 4 years

Is the UB ruptured?

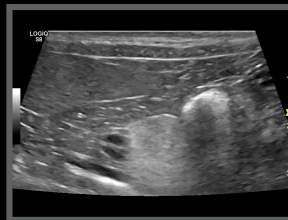Why is the peritoneum hyperechoic? 1

Probe position

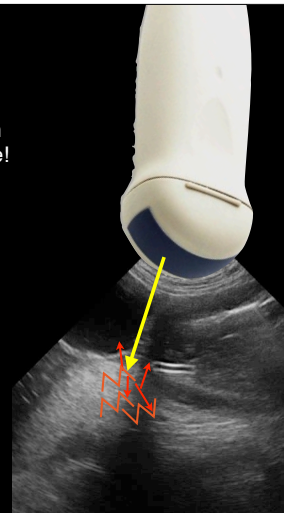


Scattering artifact

If scattering artifact is present then peritonitis and inflammation is there!

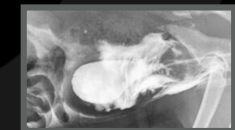
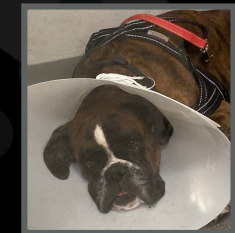

Only one exception!



Laika, Boxer, FS, 7 years

- Ruptured UB, confirmed with positive contrast
- Recovered after surgery



Conclusions

- With a systematic approach even difficult cases can be diagnosed
- Basic radiographic and ultrasonographic physic is needed to increase diagnostic accuracy



Thank you



Diagnostic Mindset

www.diagnosticmindset.com