


Milza sospetta, linfonodi irregolari, masse addominali: cosa posso dire davvero con l'ecografia?

Giliola Spattini
DVM, GP cert Cardio, CCRT, PhD, DECVDI



Diagnostic Mindset



Objectives

- The spleen and the LNs can be challenging
- How do we define what is normal?



Asso, Whippet, MI, 3 years

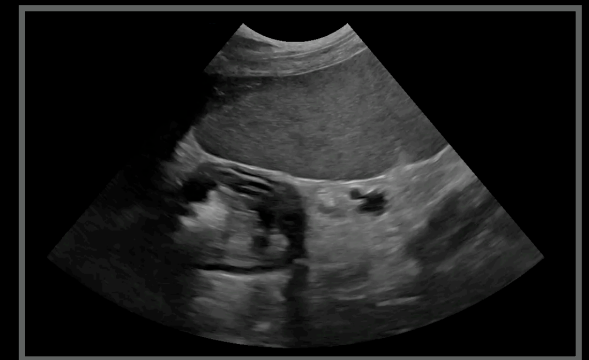
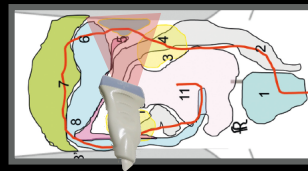
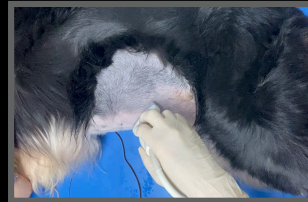- Acute vomiting
- Destroyed a toy
- Suspected FB ingestion



Asso, Whippet, MI, 3 years

Rule out FB ingestion

Probe position in a different patient



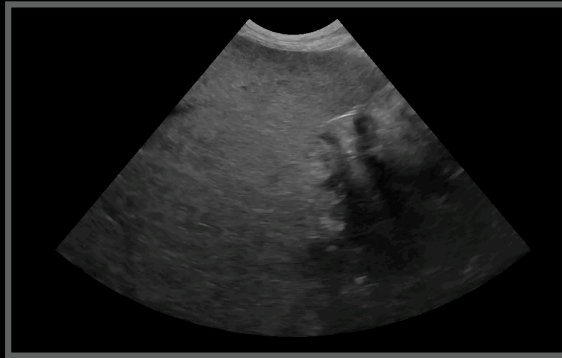
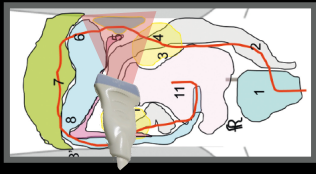
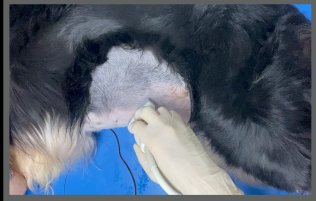
Asso, Whippet, MI, 3 years

Rule out FB ingestion



5

Probe position in a different patient



Your evaluation

Big breed big spleen



Be careful to use the words splenomegaly in dogs

Asso, Whippet, MI, 3 years

- Unremarkable spleen for the breed



Spleen

1. Margin
2. Number
3. (O) Parenchyma
4. Position
5. Size
6. Shape
7. Vascularisation
8. Surrounding peritoneum


Parenchyma

Vessels

Capsule

Splenic vein

Splenic artery



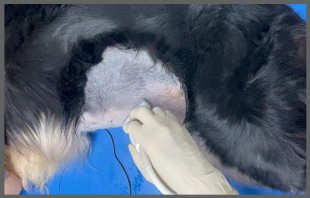
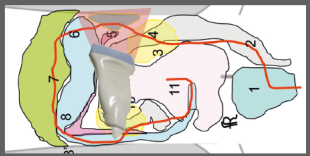

Emo, English Setter, MI, 7 years

- Lethargy
- Anorexia
- Abdominal pain
- Dyspnea



Emo, MI, 7 years

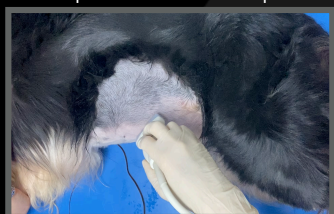
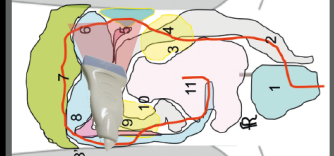

Probe position in a different patient

5

Emo, MI, 7 years

Probe position in a different patient

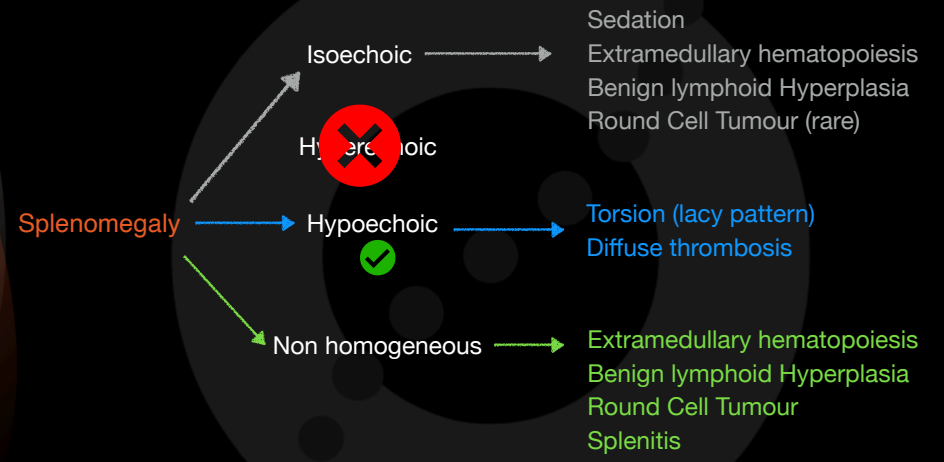
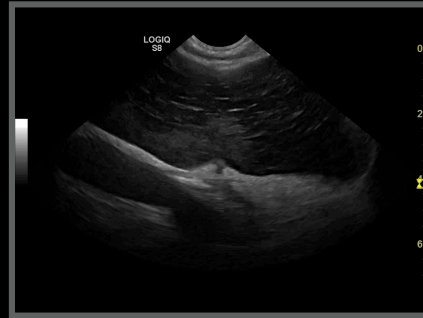5

Emo, English Setter, MI, 7 years

Splenic echostructure: Coarse
Homogeneous

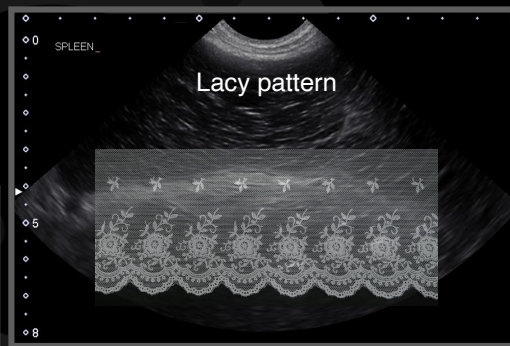
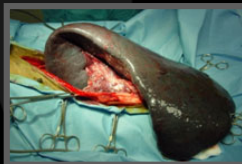Splenic echogenicity: Uniformly Reduced
Hyperechoic surrounding peritoneum

Size: "Enlarged"



Emo, English Setter, MI, 7 years

- Diffuse, large, hypoechoic spleen surrounded by scattering artifact
- Splenic torsion vs infarct
- Surgery!!



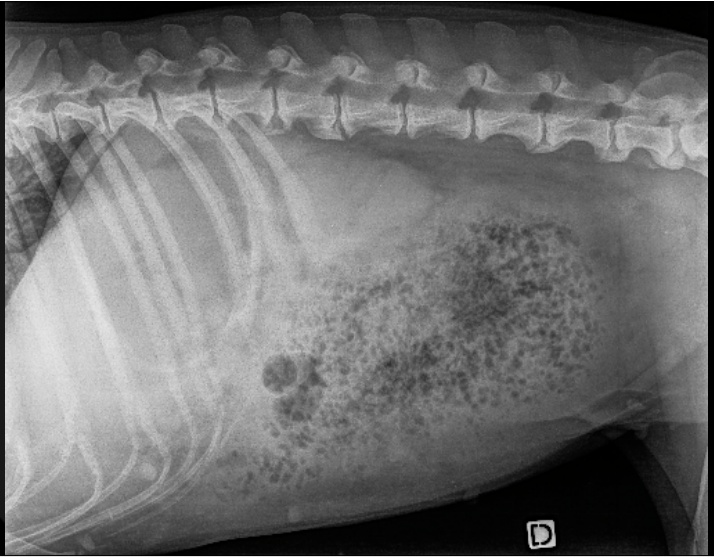
Lu, Malinois, FI, 5 years

- Anorexia
- >TRC
- Tachicardia
- 40,2°

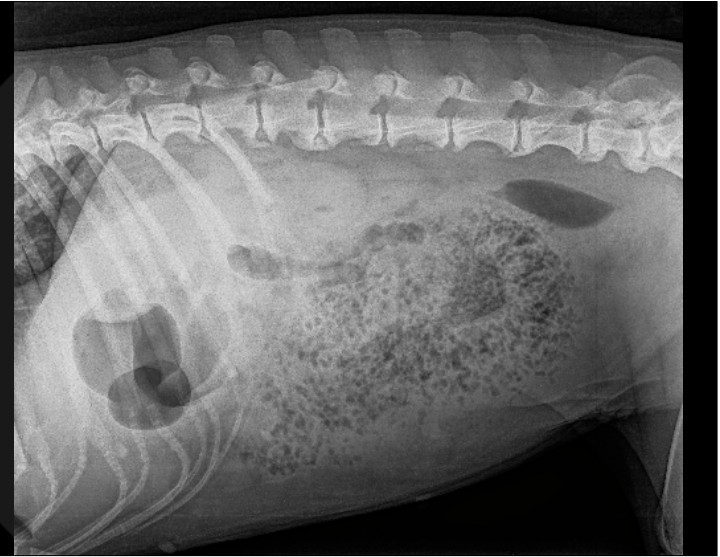


Courtesy of Dr Liotta

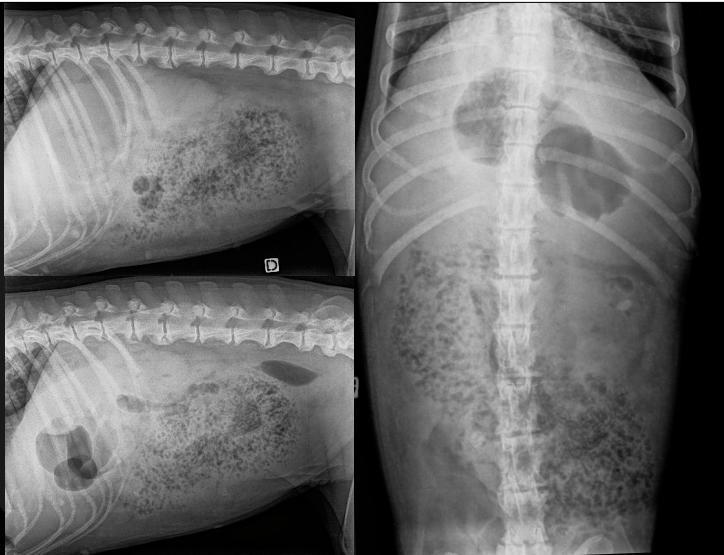Lu, FI, 5 years



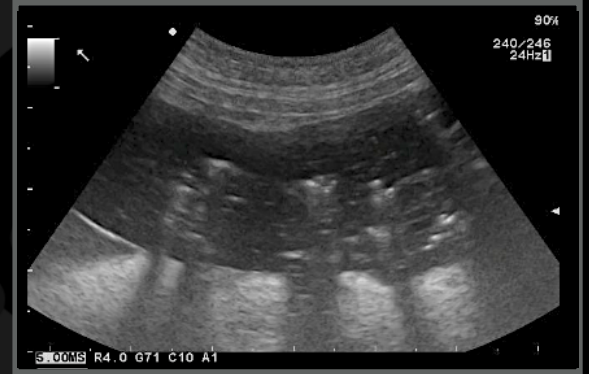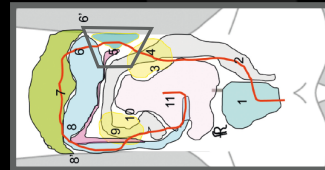
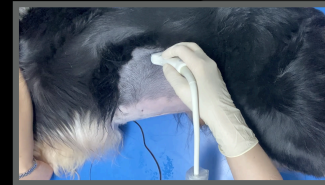Lu, FI, 5 years



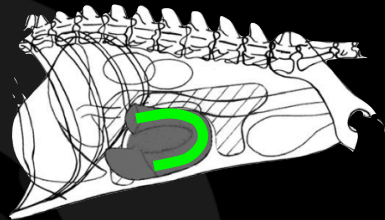
Lu, FI, 5 years



Lu, FI, 5 years



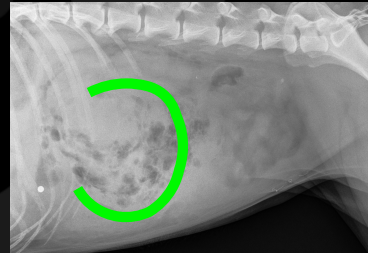
Splenic torsion



70% splenomegaly
30% abdominal effusion

4% free gas in the spleen

Large hypoechoic spleen with reduced splenic blood flow



JAVMA • Vol 248 • No. 6 • March 15, 2016

Splenic torsion

Life-threatening condition

Primary splenic torsion in dogs: 102 cases (1992–2014)

Table 3—Results of multivariate logistic regression analysis of risk factors associated with death prior to hospital discharge in dogs (n = 102) undergoing surgery because of PST.

Risk factor	OR (95%CI)	Wald P value
Preexisting septic peritonitis	32.4 (2.1–502.0)	0.013
Intraoperative hemorrhage	22.6 (1.8–289.8)	0.016
Postoperative respiratory distress	35.7 (2.7–466.0)	0.006
Weight (>10 kg)	1.6 (0.7–3.2)	0.236

Weight was a confounding variable. Hosmer-Lemeshow goodness-of-fit $P = 0.630$ (8 degrees of freedom).

Rotation of the spleen around the gastrosplenic and phrenosplenic ligaments leading to occlusion of venous drainage and arterial supply

Splenectomy favorable prognosis

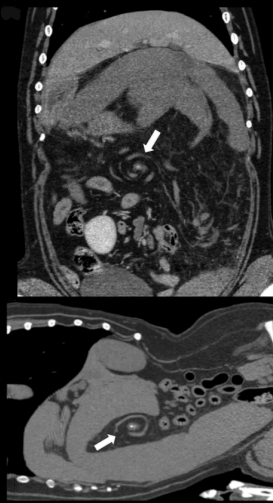
JAVMA • Vol 248 • No. 6 • March 15, 2016

Splenic torsion

CT characteristics of primary splenic torsion in eight dogs

Jonathan R. Hughes¹ | Victoria S. Johnson² | Marie-Aude Genain¹

Whirl sign alongside a strongly hyperattenuating center on the pre and post contrast images



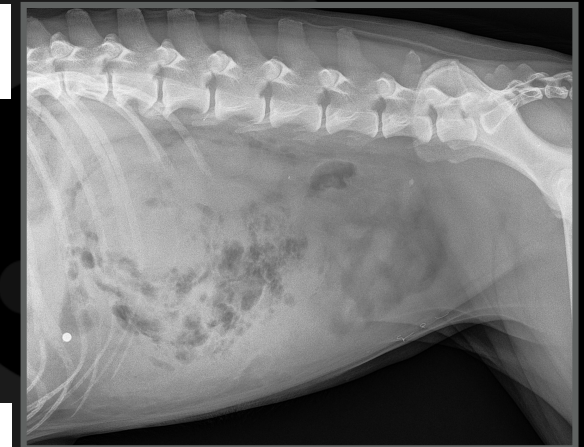Vet Radiol Ultrasound. 2020;1–8.

Emphysematous splenitis

Spontaneous emphysematous splenitis: Radiographic and ultrasonographic findings in three Golden Retriever dogs

Pierantonio Battiato¹ | Yordan Fernandez² | Raquel Salguero³ | Rosa Novellas⁴ | Yvonne Espada⁵ | David Biller⁶ | Carlo Anselmi⁷

- Mass effect
- Vesicular-like gas pattern
- Focal loss serosal detail



Vet Radiol Ultrasound. 2020;1–7.

Stella, Bloodhound, FS, 14 years

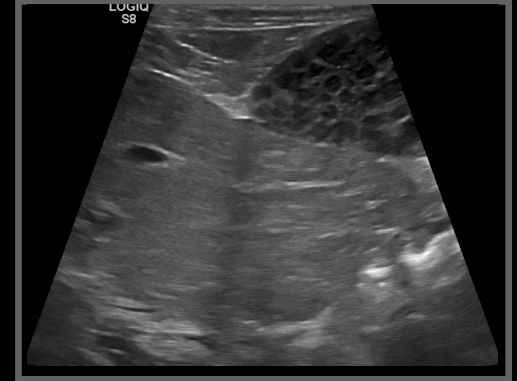
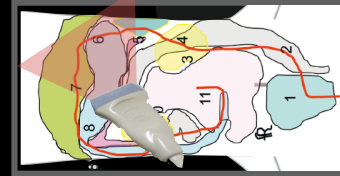
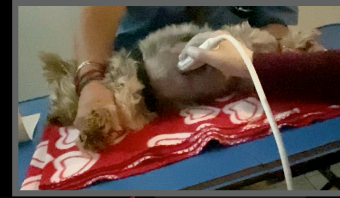- Weakness
- Dysorexia
- Abdominal pain



Stella, FS, 14 years

Probe position in a different patient

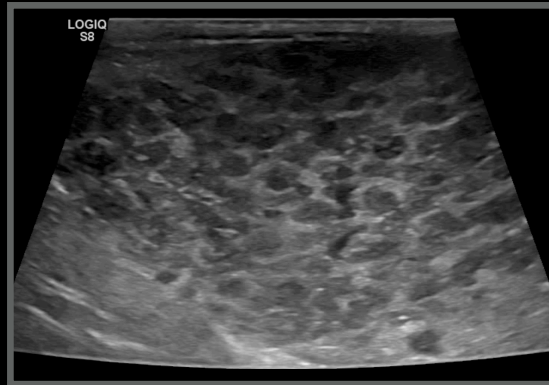
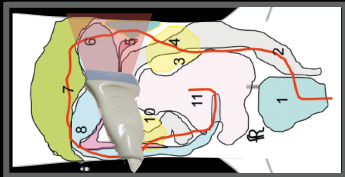
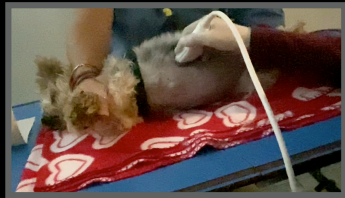6 - 5



Stella, FS, 14 years

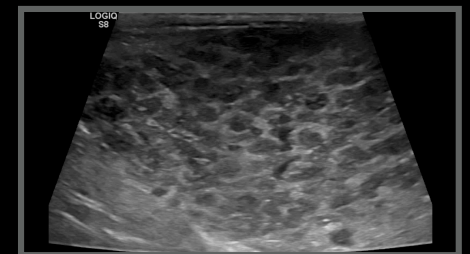
Probe position in a different patient

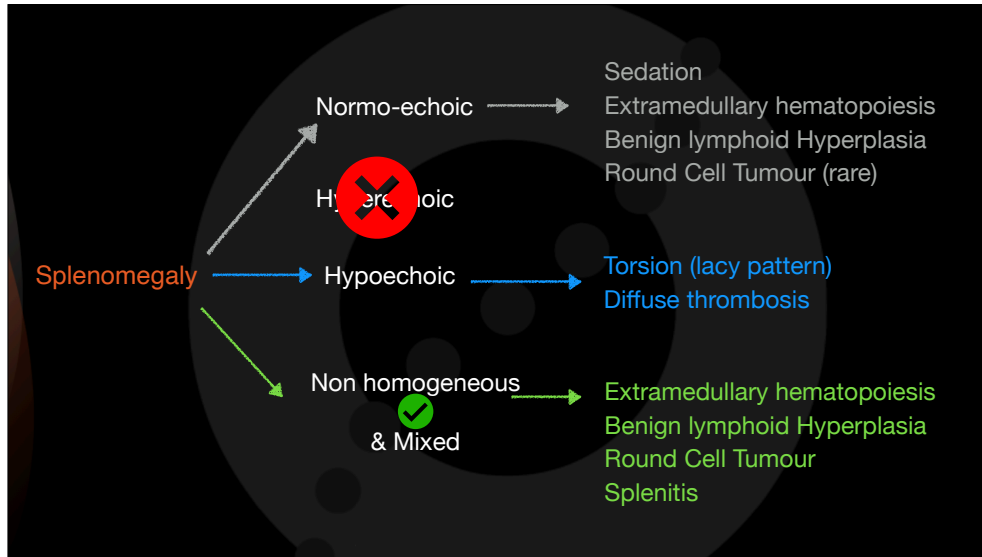
5



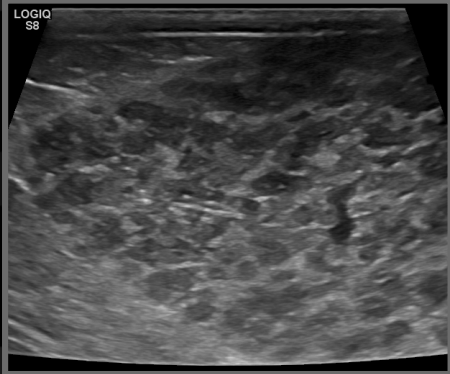
Emo, English Setter, MI, 7 years

- | | |
|------------------------|-------------------------------------|
| Splenic echostructure: | Coarse |
| | Non homogeneous |
| Splenic echogenicity: | Mixed |
| | Unremarkable surrounding peritoneum |
| Size: | "Enlarged" |





Stella, FS, 14 years



- Honeycomb parenchymal pattern
- Increased splenic size

Stella, Bloodhound, FS, 14 years

Ultrasonographic diagnoses:

- Splenopathy
- Hepatopathy
- ...



How to arrive to Conclusions:

- Physical examination
- Blood works
- Ultrasonographic findings
- Literature



PubMed® splenic diffuse pattern canine Search

Advanced Create alert Create RSS User Guide

Save Email Send to Sort by: Best match Display options

MY CUSTOM FILTERS 20 results Page 1 of 2

RESULTS BY YEAR

PUBLICATION DATE

1 year
5 years
10 years
Custom Range

TEXT AVAILABILITY

1 **Splenic diffuse heterogeneous hypoechogenicity pattern of dogs and cats: A systematic review.**
Cite Fontoura-Andrade JL.
Res Vet Sci. 2022 Dec 20;152:83-88. doi: 10.1016/j.rvsc.2022.07.016. Epub 2022 Jul 25.
PMID: 35933802
PURPOSE: This review summarized published data about the ultrasound image of the **spleen** in **dogs** and **cats** described as **diffuse** heterogeneous echogenicity **pattern** and its metaphorical terms honeycomb appearance, moth-eaten, lacy, marbled, and mottled. ...

2 **Canine nodal marginal zone lymphoma: Descriptive insight into the biological behaviour.**
Cite Cozzi M, Marconato L, Martini V, Aresu L, Riondato F, Rossi F, Stefanello D, Comazzi S.
Vet Comp Oncol. 2018 Jun;16(2):246-252. doi: 10.1111/vco.12374. Epub 2017 Dec 4.
PMID: 29205839 **Free article.**
While the clinical **behaviour** of **canine splenic** MZL has been described, characterized by an indolent course and a good prognosis following splenectomy, there are no studies specifically describing nMZL. ...A total of 35 cases were enrolled. At diagnosis, all ...

Splenic diffuse heterogeneous hypoechogenicity pattern of dogs and cats: A systematic review

Research in Veterinary Science 152 (2022) 83-88

José Luiz Fontoura-Andrade

Seção de Câncer de Guerra, Batalhão de Polícia do Exército de Brasília, Av Duque de Caxias s/n SMU, Brasília, DF 70630-100, Brasil

Conclusions: The use of more precise descriptors, such as diffuse heterogeneous echogenicity pattern, reticular or reticular-nodular pattern, is preferred over metaphorical terms such as lacy, moth-eaten, mottled, or marbled pattern. Discrete diffuse heterogeneous splenic echogenicity patterns can be missed if ultrasonographic examinations are conducted with lower-frequency transducers. Although healthy puppies or patients with various morbidities may present the diffuse heterogeneous splenic echogenicity pattern, higher prevalences were reported in canine patients with natural infection by *Babesia canis* and *Ehrlichia canis*.

The reticular pattern is the ultrasound visualization of the image of numerous hypoechoic lines with a mesh appearance. This term is derived from the Latin words *reticulum* or *reticulus*, meaning “net with small meshes”. The **reticulonodular pattern refers to an image in which there is an overlap of reticular shadows with nodular shadows or well-defined hypoechoic nodules.** Some studies differentiated the image described as mottled from that described as lacy for the same disease, whereas others grouped all patients under the more generic descriptive term “pattern of diffuse splenic heterogeneous echogenicity”. When

Stella, Bloodhound, FS, 14 years

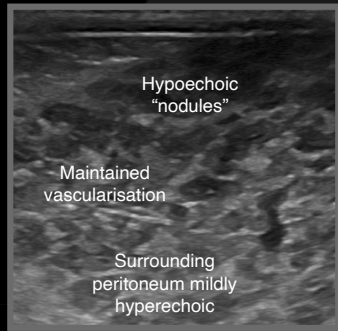
Conclusions:

- Honeycomb (reticulonodular) pattern
- Vascularisation WNL
- From unremarkable to mild surrounding peritoneal hyperechogenicity

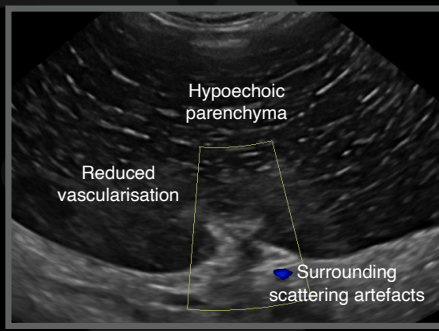
Stella, Bloodhound, FS, 14 years

- Surgical removal
- Histological diagnosis of chronic splenic leukaemia
- Survived 6 months with palliative treatment

Key points



Honeycomb or reticulonodular pattern



Lacy or reticular pattern



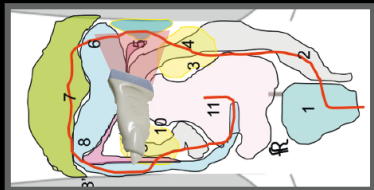
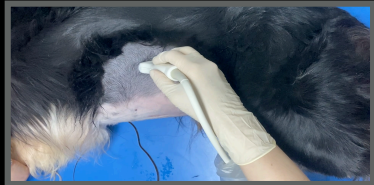Argo, Mongrel, MN, 11years

- Weakness
- Reduced appetite
- Loosing weight



Argo, MN, 11 years

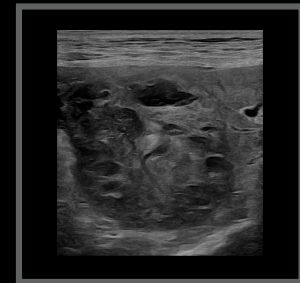
Probe position in a different patient

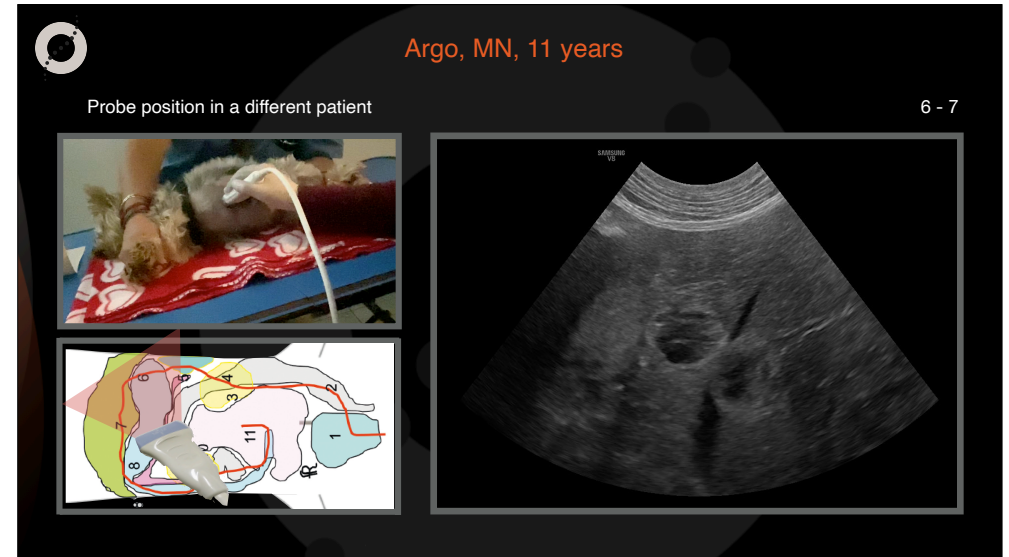
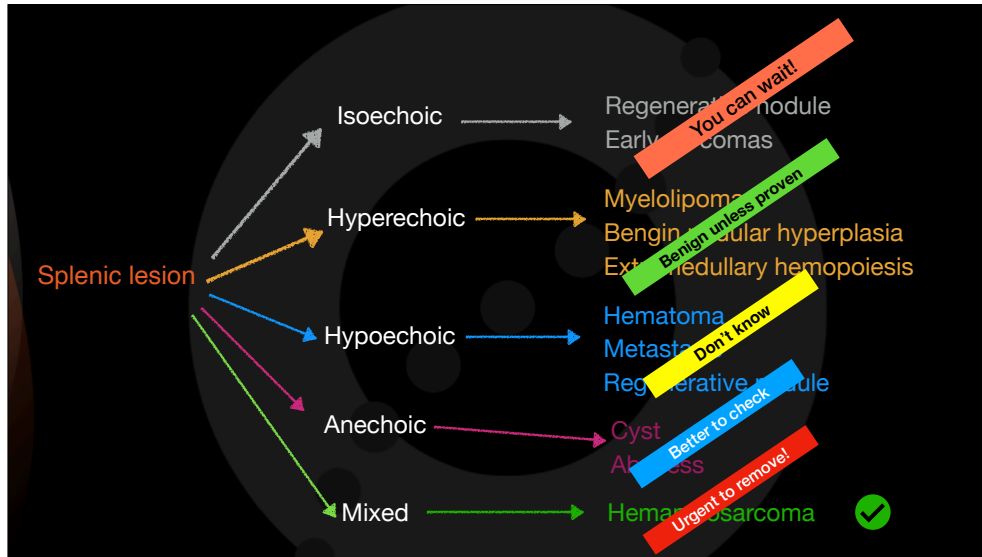


5

Argo, Mongrel, MN, 11years

- Lesion echostructure: Coarse
Non homogeneous
- Lesion echogenicity: Mixed
Focally hyperechoic surrounding peritoneum
- Capsular engagement: Yes





Target lesions

CELLULAR FEATURES OF SONOGRAPHIC TARGET LESIONS OF THE LIVER AND SPLEEN IN 21 DOGS AND A CAT

ALESSANDRA CUCCOVILLO, CHRISTOPHER R. LAMB

Target lesions are seen in ultrasound images of the liver or spleen as nodules or masses with a **hypoechoic rim and a hyperechoic or isoechoic center**. To assess the diagnostic significance of finding a target lesion, the cytologic and/or histopathologic findings were reviewed in a series of 21 dogs and a cat that had hepatic and/or splenic target lesions noted during abdominal ultrasonography. Twelve of 16 hepatic target lesions and 5 of 7 splenic target lesions were malignant. In this series, the finding of **one or more target lesions in the liver or spleen had a positive predictive value for malignancy of 74%**; for the finding of **multiple target lesions in one organ, the positive predictive value for malignancy was 81%**. Benign lesions associated with target lesions were nodular hyperplasia of the liver and spleen, pyogranulomatous hepatitis, cirrhosis, and chronic active hepatitis. *Veterinary Radiology & Ultrasound, Vol. 43, No. 3, 2002, pp 275-278.*

Argo, Mongrel, MN, 11 years

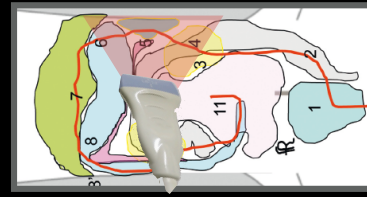
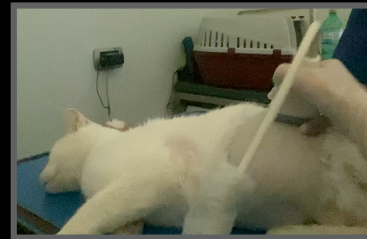- Surgical splenic removal
- Hemangiosarcoma on histology
- Hepatic metastasis
- 5 months survival

Bill, DSH, MN, 14 years

- Loosing weight
- Poor coat
- A large nodule palpated in the thyroid region

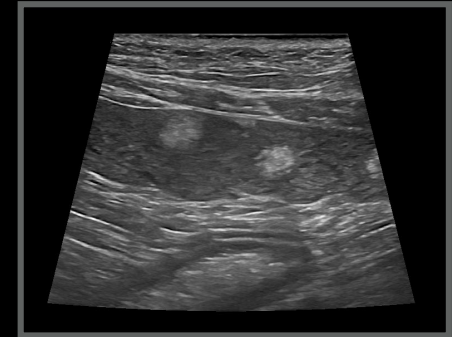


Probe position in a different patient



Argo, MN, 11 years

5



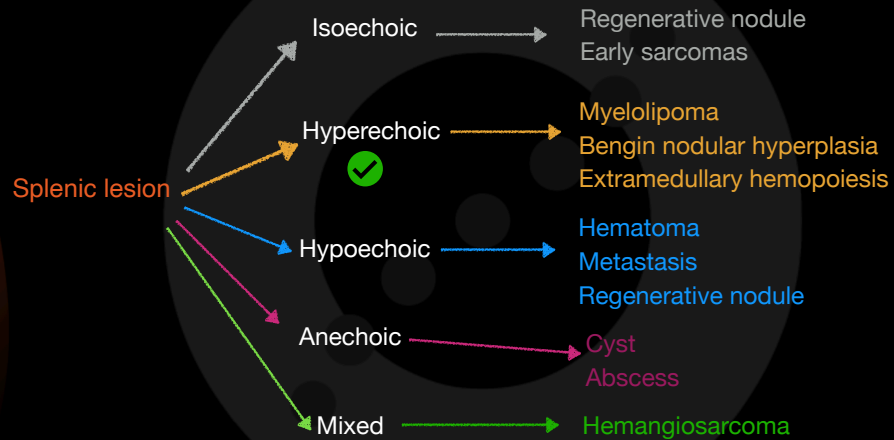
Bill, DSH, MN, 14 years

Ultrasonographic diagnoses:

- Multifocal hyperechoic nodular lesions
- Splenopathy



Final diagnosis: granulomas, suspected of parasitic origine



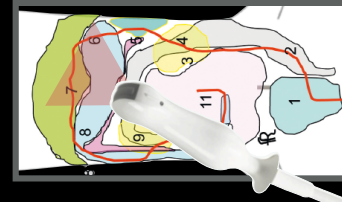
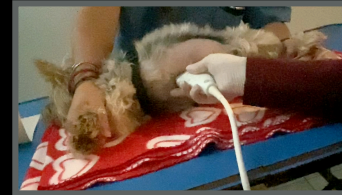Bracco, Doberman, MI, 4 years

- One month of diarrhoea, now hemorrhagic, dark faeces
- Vomiting, some blood in it
- Diagnosed with lymphoma by an abdominal ultrasound

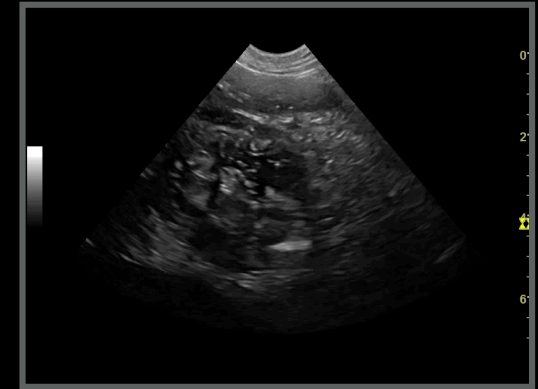

Bracco, MI, 4 years

Probe position in a different patient

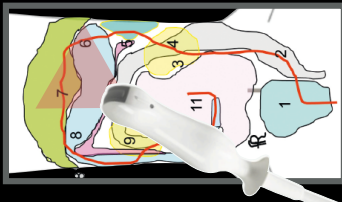
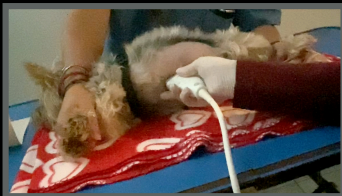

7 trans

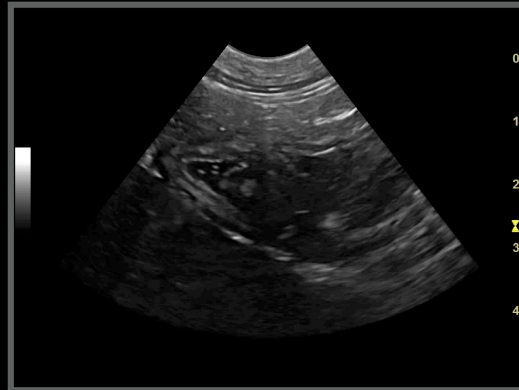

Bracco, MI, 4 years

Probe position in a different patient

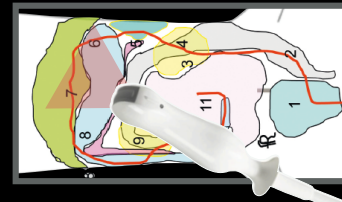
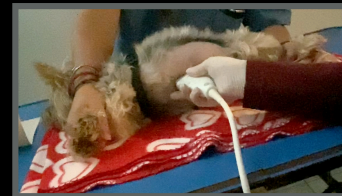

7 trans

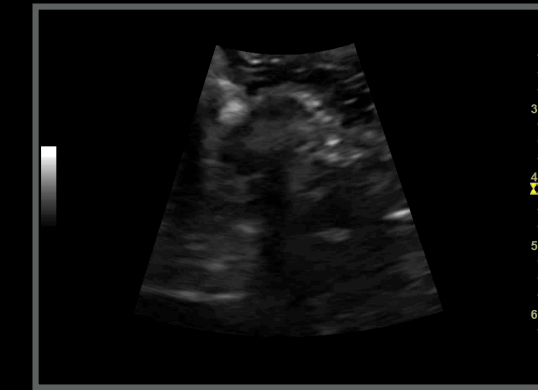


Bracco, MI, 4 years

Probe position in a different patient

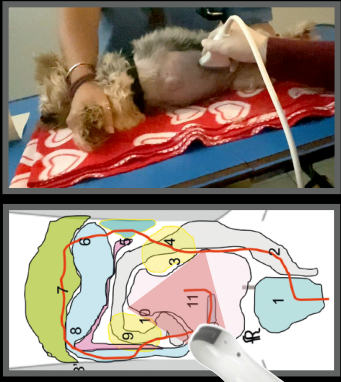

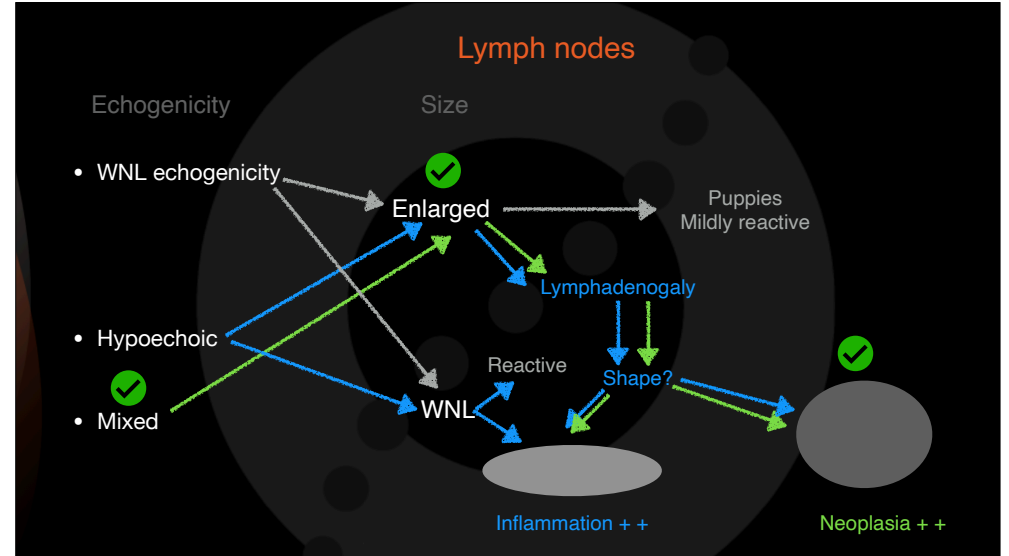


7 trans



Bracco, MI, 4 years

Probe position in a different patient 10-11

The Sonographic Evaluation of Lymph Nodes

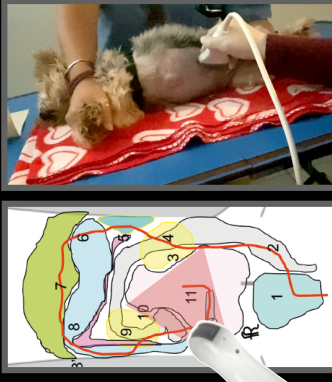

Helena T. Nyman, DVM, MSc, PhD* and Robert T. O'Brien, DVM, MS, DACVR[†]

Ultrasound can be used to detect and evaluate both normal and abnormal lymph nodes, as well as aid in biopsy sampling procedures, an important part of staging procedures in cancer patients. Several parameters can be evaluated using ultrasound; lymph node size, margins, echogenicity, echopattern (echotexture), acoustic transmission, presence and distribution of vascular flow, and vascular flow indices. The most diagnostically helpful include the short/long axis ratio of the lymph node, the pattern of distribution of the blood vessels within the lymph node, and to some extent the resistive and pulsatility indices. This review discusses the use of ultrasound for detecting, evaluating, and sampling peripheral, abdominal and thoracic lymph nodes in small animals.
Clin Tech Small Anim Pract 22:128-137 © 2007 Elsevier Inc. All rights reserved.

	Malignant Lymph Nodes	Benign Lymph Nodes
S/L axis	>0.7	<0.7
Hilus	Narrow or absent	Usually present
Echogenicity	Often hypoechoic	Isoechoic
Blood flow distribution	Primarily peripheral or mixed	Hilar

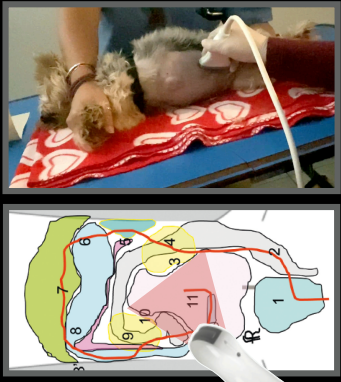

Bracco, MI, 4 years

Probe position in a different patient 10-11

Bracco, MI, 4 years

Probe position in a different patient 10-11





Bracco, Doberman, MI, 4 years

Ultrasonographic diagnoses:

- Focal gastric thickening
- Mesenteric lymphomegaly - nodular lesions
- Intramural, asymmetric, concentric colonic mass

Two GE lesions




PubMed® multiple gastrointestinal masses canin

Advanced Create alert Create RSS User Guide

Save Email Send to Sorted by: Best match Display options

MY NCBI FILTERS 3 results Page 1 of 1

RESULTS BY YEAR



TEXT AVAILABILITY

Abstract

Free full text

Full text

ARTICLE ATTRIBUTE

Associated data

ARTICLE TYPE

Books and Documents

Clinical Trial

Meta-Analysis

Randomized Controlled

1 **MAST CELL TUMORS IN CHEETAH (*ACINONYX JUBATUS*): A CASE SERIES.**
Campbell-Ward ML, Bryant BR, Peaston AE, Tamin V, Tong L, Sangster C.
J Zoo Wildl Med. 2021 Jan;51(4):1025-1034. doi: 10.1638/2020-0006.
PMID: 33480586
Share
The age at initial presentation varied from 14 mo to 6 yr. Four cases presented as solitary or multiple cutaneous masses that were mostly slow growing, up to 20 mm diameter, and predominantly nonulcerated. ...There was no evidence of lymph node invasion or paraneop...

2 **Gastric B-cell lymphoma with Mott cell differentiation in a dog.**
De Zan G, Zappulli V, Cavicchioli L, Di Martino L, Ros E, Conforto G, Castagnaro M.
J Vet Diagn Invest. 2009 Sep;21(5):715-9. doi: 10.1177/104063870902100521.
PMID: 19737772
Share
A gastric lymphoid tumor with involvement of regional lymph nodes and spleen was diagnosed in an 8-year-old crossbred male dog with a 6-month history of gastrointestinal disease. Despite surgical excision and palliative therapy (prednisolone and cimetidine), the dog was e ...

3 **Pancreatic polypeptide and insulin-secreting tumor in a dog with duodenal ulcers and hypertrophic gastritis.**
Zerbe CA, Boosinger TR, Grabau JH, Pletcher JM, O'Dorizio TM.
J Vet Intern Med. 1989 Jul-Sep;3(3):178-82. doi: 10.1111/j.1939-1676.1989.tb03095.x.
PMID: 2674425 Free article.
Laboratory abnormalities included leukocytosis, metabolic alkalosis, hypoglycemia, hypoproteinemia, and hyperinsulinemia. Gastroscopy and ultrasonography revealed multiple gastric masses and a possible pancreatic mass, respectively. ...The high PP values may have re ...

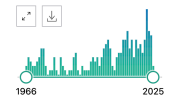
PubMed® ultrasound gastrointestinal tumor canin

Advanced Create alert Create RSS User Guide

Save Email Send to Sorted by: Best match Display options

MY CUSTOM FILTERS 223 results Page 1 of 23

RESULTS BY YEAR



PUBLICATION DATE

1 year

5 years

10 years

Custom Range

TEXT AVAILABILITY

Abstract

Free full text

Full text

ARTICLE ATTRIBUTE

Associated data

ARTICLE TYPE

1 **Ultrasonographic Appearance of Gallbladder Neoplasia in 14 Dogs and 1 Cat.**
MacLeod AN, Reichle JK, Szabo D, Cohen EB, Artiles C, Fulkerson CV, Kurihara M, Mattoon J.
Vet Radiol Ultrasound. 2023 May;64(3):537-545. doi: 10.1111/vru.13227. Epub 2023 Mar 3.
PMID: 36867397
Share
Ultrasonography is the most commonly used diagnostic imaging tool for gallbladder disease in veterinary medicine. ...The final diagnosis of the gallbladder neoplasia was neuroendocrine carcinoma (8), leiomyoma (3), lymphoma (1), gastrointestinal stroma ...

2 **ULTRASONOGRAPHIC FEATURES OF CANINE GASTROINTESTINAL STROMAL TUMORS COMPARED TO OTHER GASTROINTESTINAL SPINDLE CELL TUMORS.**
Hobbs J, Sutherland-Smith J, Penninck D, Jennings S, Barber L, Barton B.
Vet Radiol Ultrasound. 2015 Jul-Aug;56(4):432-8. doi: 10.1111/vru.12253. Epub 2015 Apr 1.
PMID: 25846814
Share
Canine gastrointestinal stromal tumors (GISTs) are a recent subtype of gastrointestinal spindle cell tumor recognized with the increasing use of immunohistochemistry. ...Gastrointestinal stromal tumors were significantly more likely to be associ ...

3 **Alimentary neoplasia in geriatric dogs and cats.**
Willard MD.
Vet Clin North Am Small Anim Pract. 2012 Jul;42(4):693-706. vi. doi: 10.1016/j.cvsm.2012.04.006. Epub 2012 May 10.
PMID: 22720809 Review.
Lymphomas, carcinomas, leiomyomas, and stromal tumors are the most common tumors found in the canine and feline gastrointestinal tract. Endoscopic and surgical biopsies are often the mainstays of diagnosis, although ultrasound is playing an increasingly great ...

DIAGNOSTIC VALUE OF ULTRASONOGRAPHY IN DIFFERENTIATING ENTERITIS FROM INTESTINAL NEOPLASIA IN DOGS

Veterinary Radiology & Ultrasound, Vol. 44, No. 5, 2013, pp 570-575.

DOMINIQUE PENNINGK, DVM, DVSc; BETHANY SMYERS, BS, CYNTHIA R.L. WEBSTER, DVM, WILLIAM RAND, PhD, ANTONY S. MOORE, BVSc, MVSc

Parameter	Enteritis	Neoplasia
Medium wall thickness	6 mm	15 mm
Loss wall layering	11%	99%
More than 1 lesion	72%	2%
Decreased regional motility	61%	87%

How to arrive to Conclusions:

- PE examination
 - Blood works
 - Ultrasonographic findings
 - Literature
- Loosing blood
- Possible enteritis???
- Multiple lesions



PubMed®

bleeding doberman

Search

Advanced Create alert Create RSS

User Guide

Save Email Send to

Sort by: Best match

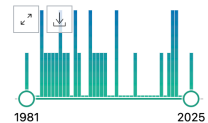
Display options

MY CUSTOM FILTERS

29 results

Page 1 of 3

RESULTS BY YEAR



PUBLICATION DATE

- 1 year
- 5 years
- 10 years
- Custom Range

TEXT AVAILABILITY

- Abstract

1 **Canine Von Willebrand's Disease: A Common Inherited Bleeding Disorder in Doberman Pinscher Dogs.**

Cite

Johnstone IB.

Can Vet J. 1986 Sep;27(9):315-8.

PMID: 17422688 [Free PMC article.](#)

Von Willebrand's disease is the most common inherited **bleeding** disorder of dogs occurring with particularly high frequency in **Doberman** pinscher dogs. ..."Stress" may be required to make the increased **bleeding** tendency clinically apparent. This report describe ...

2 **Effect of desmopressin acetate on bleeding times and plasma von Willebrand factor in Doberman pinscher dogs with von Willebrand's disease.**

Cite

Kraus KH, Turrentine MA, Jergens AE, Johnson GS.

Vet Surg. 1989 Mar-Apr;18(2):103-9. doi: 10.1111/j.1532-950x.1989.tb01051.x.

PMID: 2786279

Effects of desmopressin acetate (1-desamino-8-D-arginine vasopressin [DDAVP]) on plasma von Willebrand factor (vWf) were studied in 12 purebred **Doberman** pinschers confirmed to have von Willebrand's disease (vWd) (plasma vWf antigen [vWf:Ag] concentrations, less than 30 U/d ...

Bracco, Doberman, MI, 4 years

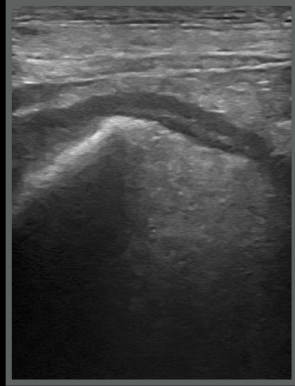
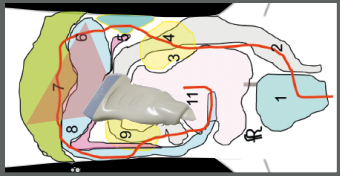

- Tested for Von Willebrand factor: positive
- Genetic screening: positive
- Treated for chronic enteritis



Bracco, MI, 4 years
Two months recheck

Probe position in a different patient

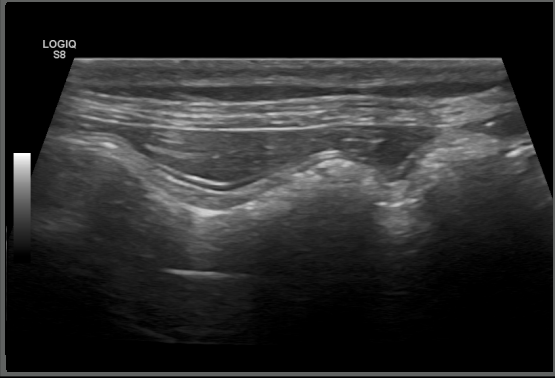
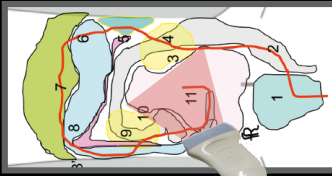

7 trans

Bracco, MI, 4 years
Two months recheck

Probe position in a different patient

10-11

Bracco, Doberman, MI, 4 years

Conclusions

- Mild lymphocytic-plasmacytic enteritis
- Von Willebrand


Follow up

Still doing fine two years later but overweight



Poldo, Chihuahua, MI, 12 years

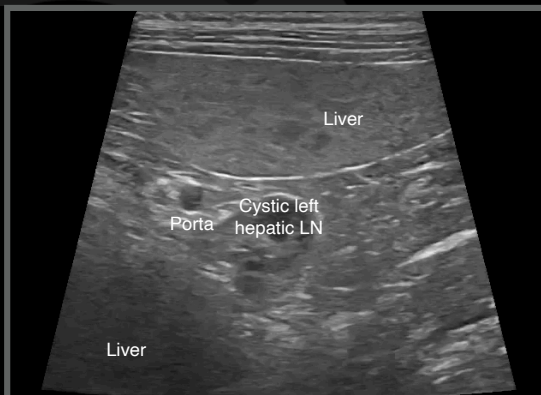
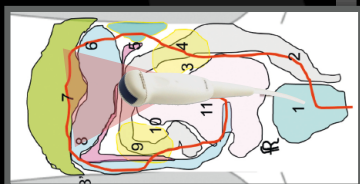
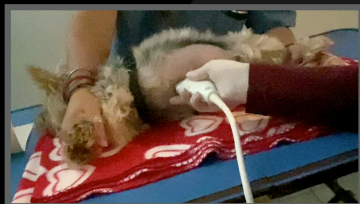
- PU/PD
- Pot belly
- Thin hair and alopecia



Poldo, MI, 12 years

Probe position in a different patient

7-6



Prevalence, location and concurrent diseases of ultrasonographic cyst-like lesions of abdominal lymph nodes in dogs

Veterinary Record (2017)

doi: 10.1136/vr.103795

A. Liotta, F. Billen, M. Heimann, A. Hamaide, M. Rizza, A. L. Etienne, G. Bolen

Lymph nodal cyst-like lesions are occasionally identified during abdominal ultrasound in dogs. However, a study evaluating their prevalence and clinical significance is lacking. The aim of this observational cross-sectional study was to evaluate prevalence, most common location and concurrent diseases of cyst-like lymph nodes detected during abdominal ultrasound. Affected lymph nodes, patient signalment and concurrent diseases of dogs with

Histologically, in the present study, the lymph nodal cyst-like lesions detected by ultrasonography corresponded to sinusoid ectasia or haemorrhagic cavities.

(8/23), followed by neoplasia (7/23), gastroenteropathy (3/23), benign prostatic disease (2/23), pancreatitis (1/23), peritonitis (1/23) and neurological disease (1/23). No statistical correlation existed between cyst-like lymph nodal lesion and a specific neoplastic or non-neoplastic disease. In conclusion, in the present study, cyst-like lymph nodal lesions have a low prevalence, involve different lymphocenters and were found in dogs affected by different diseases, including both non-neoplastic and neoplastic aetiologies.

Poldo, Chihuahua, MI, 12 years

Conclusions

- Suspected hyperadrenocorticism
- Cystic LN - incidental finding



Active pituitary adenoma confirmed on blood works and CT

Conclusions

- The spleen may show breed related variations in normal anatomy
- Ultrasound is not histologically specific, particularly in lymphoid organs



Thank you



Diagnostic Mindset

www.diagnosticmindset.com