


Discussione interattiva di casi clinici complessi

Giliola Spattini
DVM, GP cert Cardio, CCRT, PhD, DECVDI



Mefisto, DSH, MI, 18 months

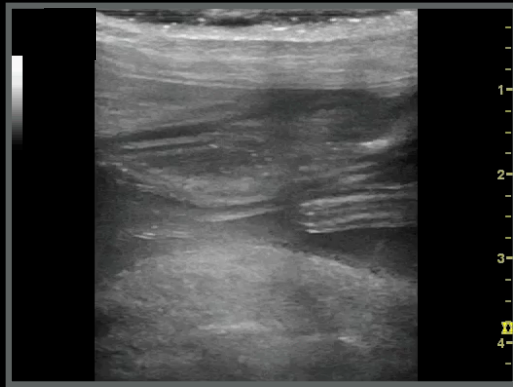
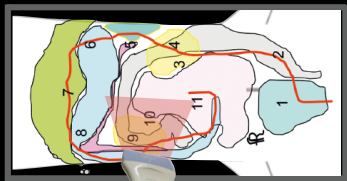
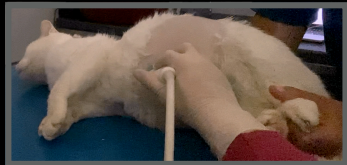- Loosing weight
- Diarrhea
- Anorexia
- FIV and FELV positive



Mefisto, MI, 18 months

Probe position in a different patient

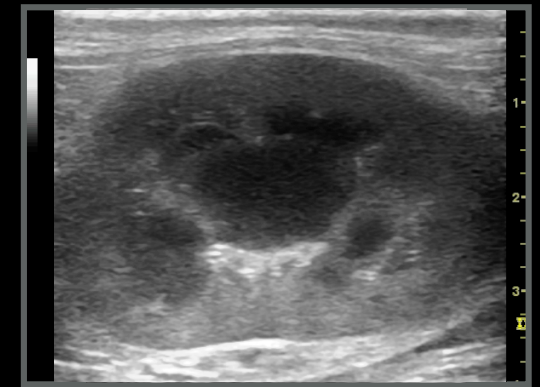
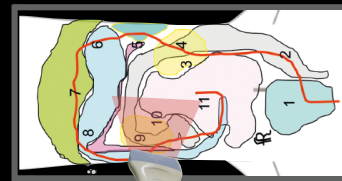
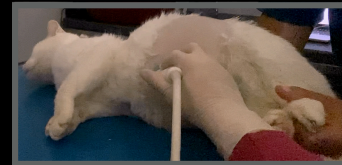
7-11



Mefisto, MI, 18 months

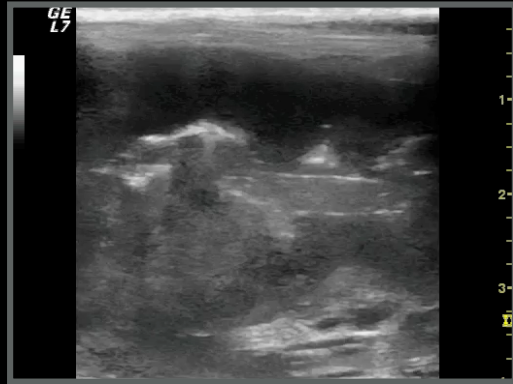
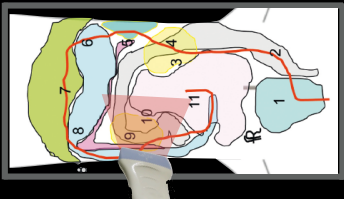
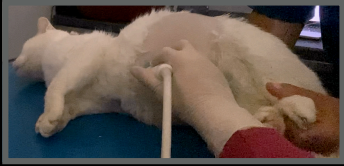
Probe position in a different patient

7-11



Mefisto, MI, 18 months

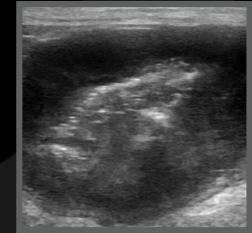
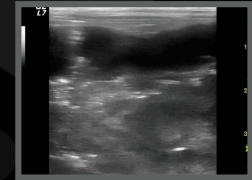
Probe position in a different patient



7-11

Mefisto, DSH, MI, 18 months

- Reverberation artifact
- Intestinal mass



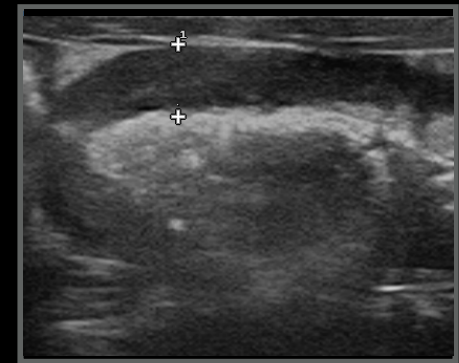
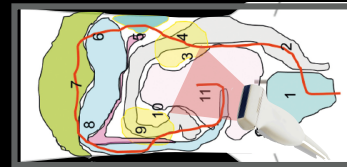
Pallino, DSH, MN, 2 years

- Treated conservatively for pyothorax
- Pernicious vomiting



Pallino, MN, 2 years

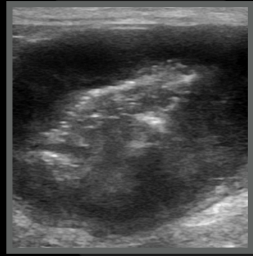
Probe position in a different patient



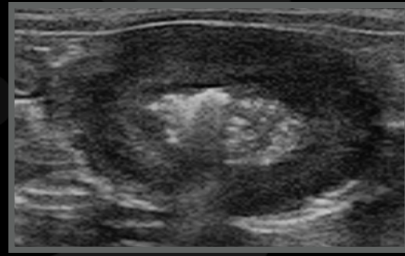
10-11

Mefisto, DSH, MI, 18 months

Pallino, DSH, MN, 2 years



• Large cells lymphoma



• Eosinophilic sclerosing fibroplasia

Neoplasia Inflammation

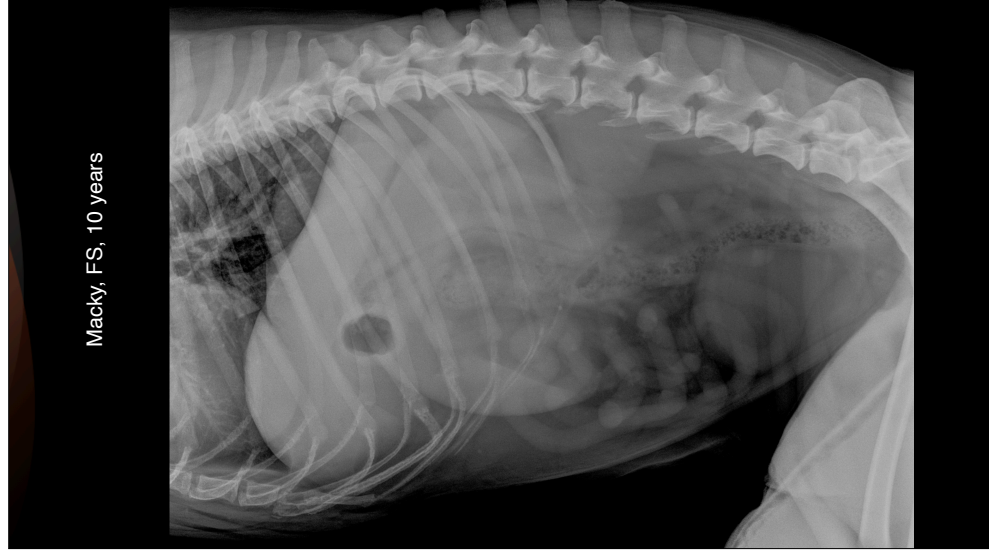
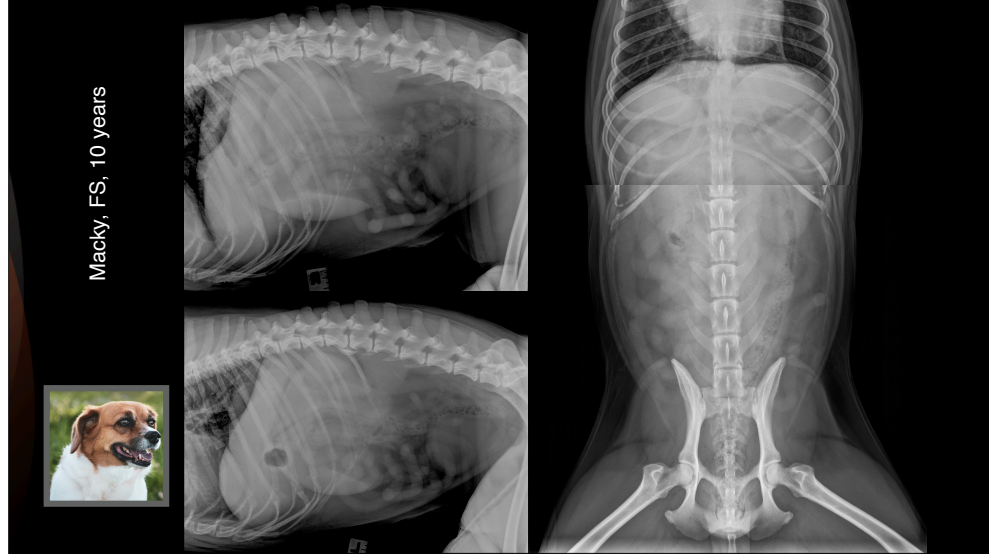
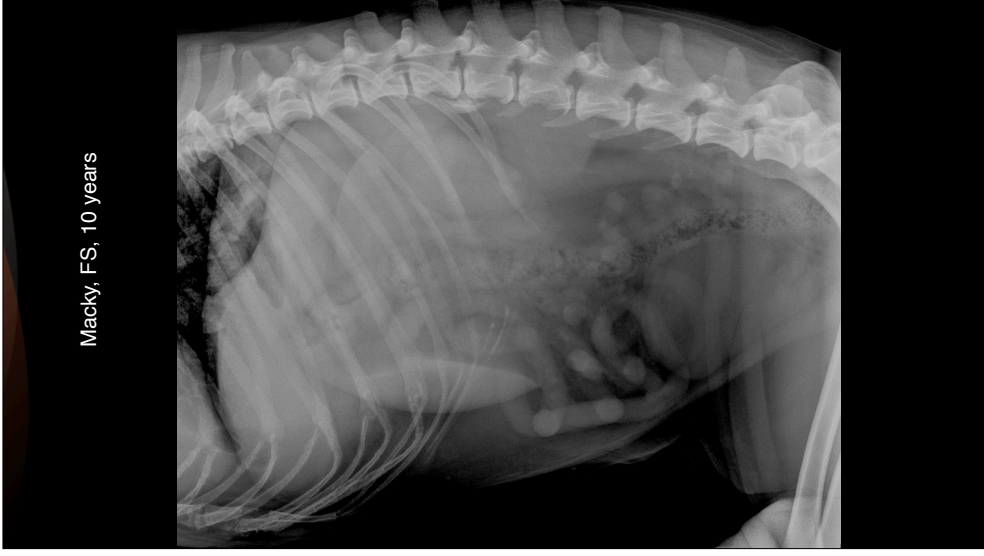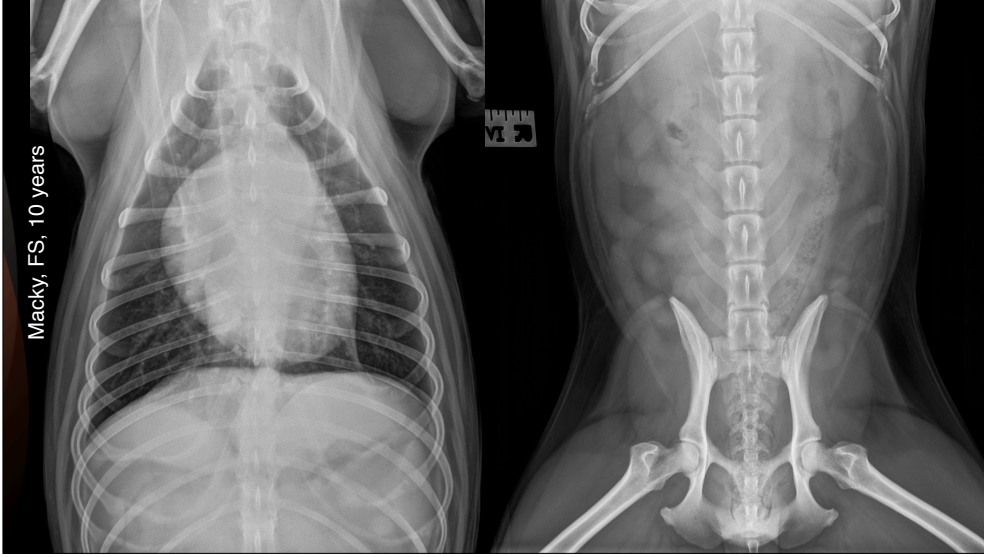
THICKNESS OF THE WAL	15 MM	6 MM
WALL LAYERING	99% LOST	88 % NORMAL
NUMBER OF LESIONS	2% MORE THAN ONE LESIONS	72% AT LIST TWO LESIONS
AVERAGE THICKNESS OF THE TRIBUTARY LYMPH NODES	1,9 CM	1,0 CM

ADENOCARCINOMA	LYMPHOMA	LEYOMIOMA
SYMMETRIC	SYMMETRIC	ASYMMETRIC
SHORT, NO MORE THAN 3,5 CM	USUALLY MORE THAN 3,5 CM	LONG AND LARGE
USUALLY QUICKLY OBSTRUCTIVE	CAN BECOME OBSTRUCTIVE	USUALLY IT IS NOT OBSTRUCTIVE
REGIONAL LN NEARLY ALWAYS AFFECTED	REGIONAL LN USUALLY AFFECTED	REGIONAL LN USUALLY NOT AFFECTED
CAN BE ULCERATED	CAN BE ULCERATED	ULCERATION IS RARE

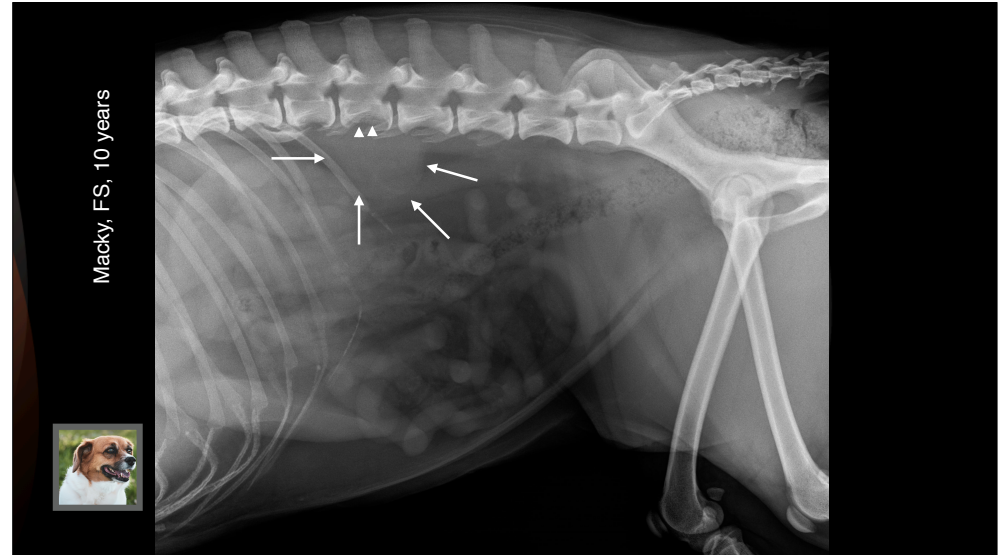
Macky, Mongrel, FS, 10 years

- One week of weakness during walks
- Yelped if touched on the flank
- Trouble setting





Your evaluation



Macky, Mongrel, FS, 10 years

Radiographic diagnoses:

- Focal retroperitoneal soft tissue mass
- Adjacent lytic lesion of the vertebral body



Conclusions

- FNA and biopsy confirmed a soft tissue sarcoma arising from the iliopsoas muscle
- Survived with radiation for 18 months

Spriz, Maine Coon, MN, 4 months

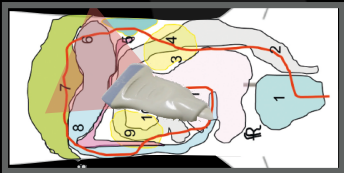
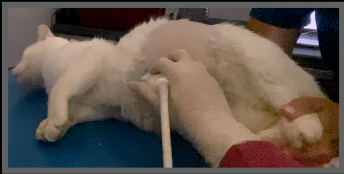- Castrated and donated the next day
- Depressed
- Not eating
- Elevated renal values

Urea (mg/dL):	273	20-65
Creatinina (mg/dL):	6.45	0.7-1.6
Fosforo (mg/dL):	17.3	2.6-5.0



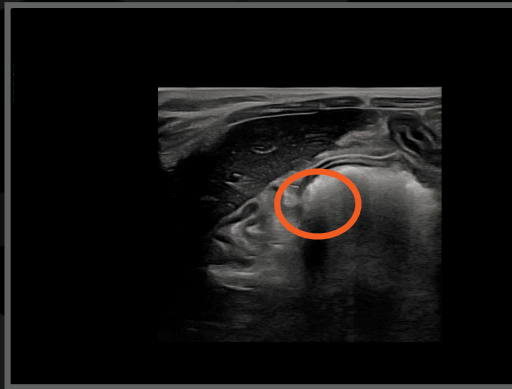
Spriz, MN, 4 months

Probe position in a different patient



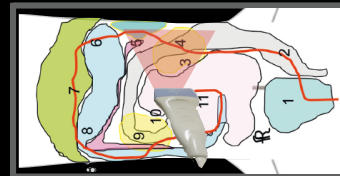
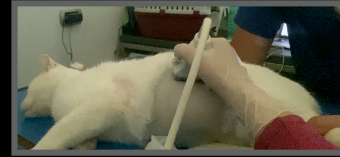Gastric LN

6-7



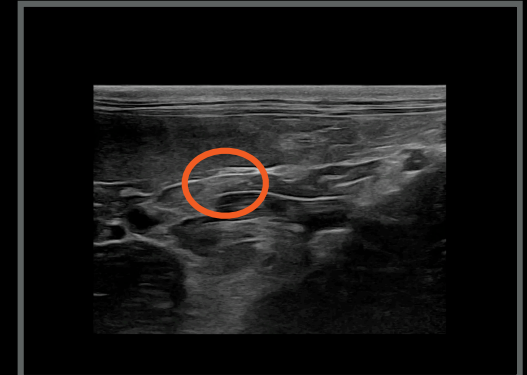
Spriz, MN, 4 months

Probe position in a different patient



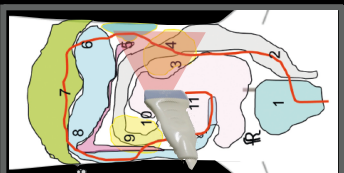
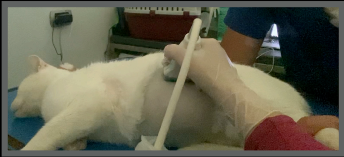Splenic LN

5



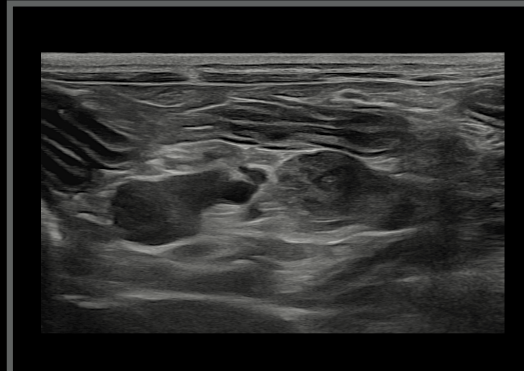
Spriz, MN, 4 months

Probe position in a different patient



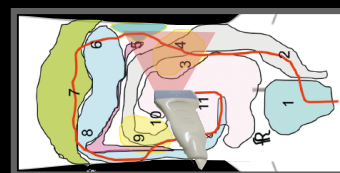
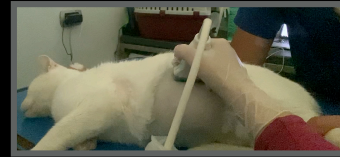Jejunal LNs

5-11



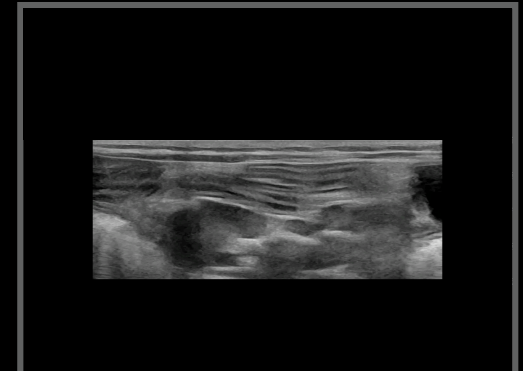
Spriz, MN, 4 months

Probe position in a different patient



Jejunal LNs

5-11

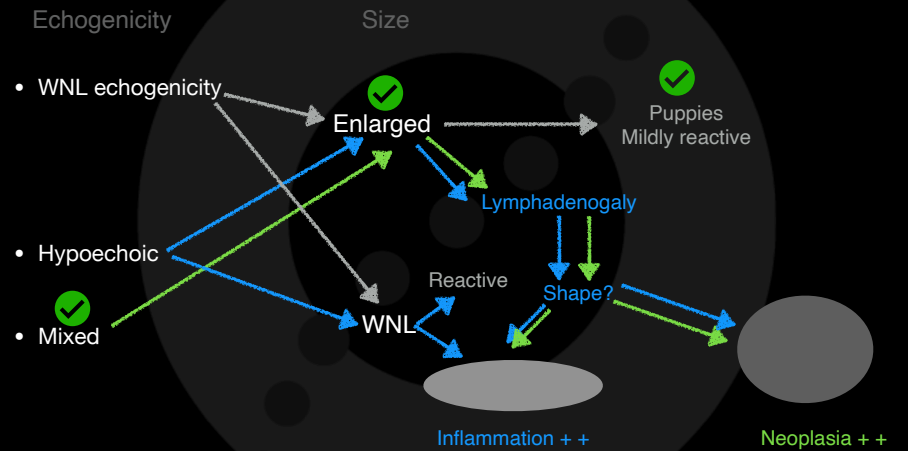


Spriz, Maine Coon, MN, 4 months



- Are the LNs abnormal?
- Could this patient have a FIP?
- What would you do next?

Lymph nodes



Spherix index


$H / L < 0,7$

Inflammation more likely



$H / L < 0,7$

Neoplasia more likely



Ultrasonographic assessment of abdominal lymph nodes in puppies.

Krol L, O'Brien R.

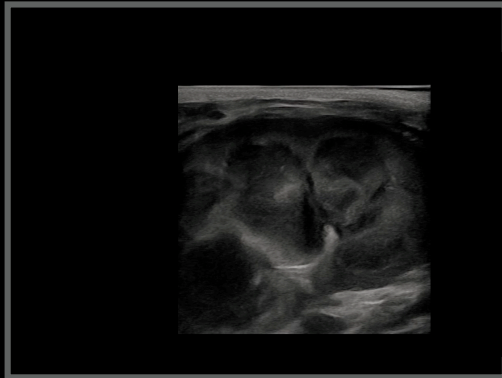
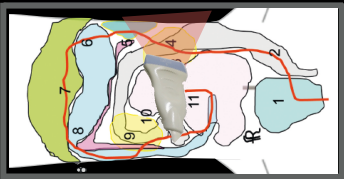
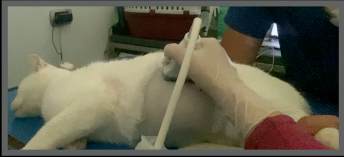Vet Radiol Ultrasound. 2012 Jul-Aug;53(4):455-8. doi: 10.1111/j.1740-8261.2012.01932.x. Epub 2012 Apr 12. PMID: 22497669

variety of shapes were seen, including vermiform and complex branching shapes. We concluded that in 4- to 6-week-old dogs, medial iliac lymph nodes are similar in size to adult dogs and jejunal lymph nodes are multiple, routinely seen, are larger than in adults and often have unconventional shapes.

Spriz, MN, 4 months

Probe position in a different patient

4

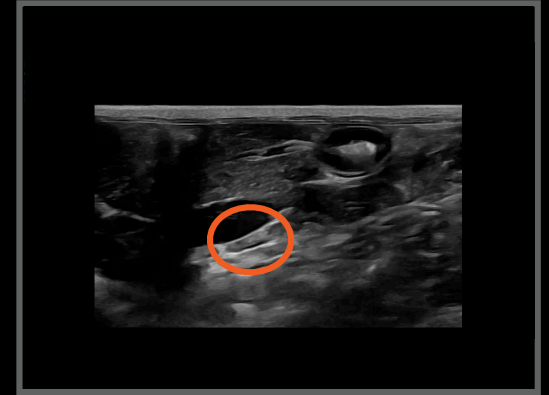
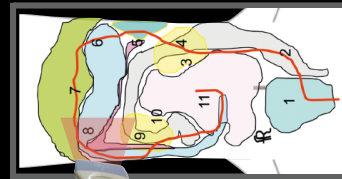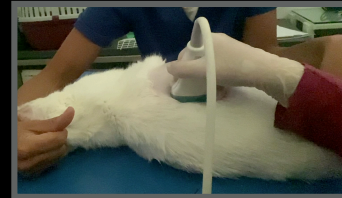


Spriz, MN, 4 months

Probe position in a different patient

Hepatic LNs

8-8'

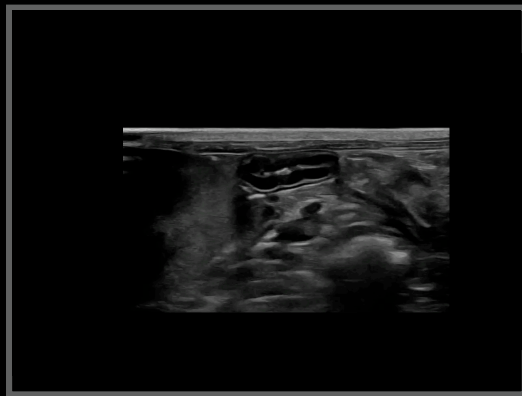
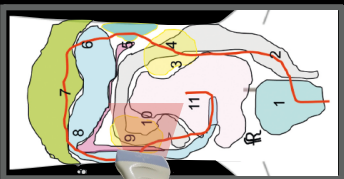
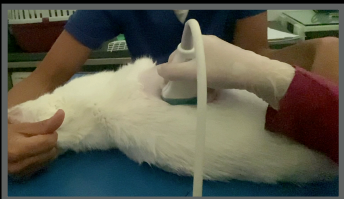

Spriz, MN, 4 months

Probe position in a different patient

Right colic LNs

10



Spriz, Maine Coon, MN, 4 months

- Decreased cortical renal perfusion
- Hypotension?
- Clinically recovered in 24 hours

Urea (mg/dL):	42	20-65
Creatinina (mg/dL):	0.69	0.7-1.6
Glucosio (mg/dL):	73	80-145
Calcio (mg/dL):	8.1	8.0-11.2
Fosforo (mg/dL):	5.6	2.6-5.0

- Recheck renal vascularisation in one week
- Still doing fine two months later

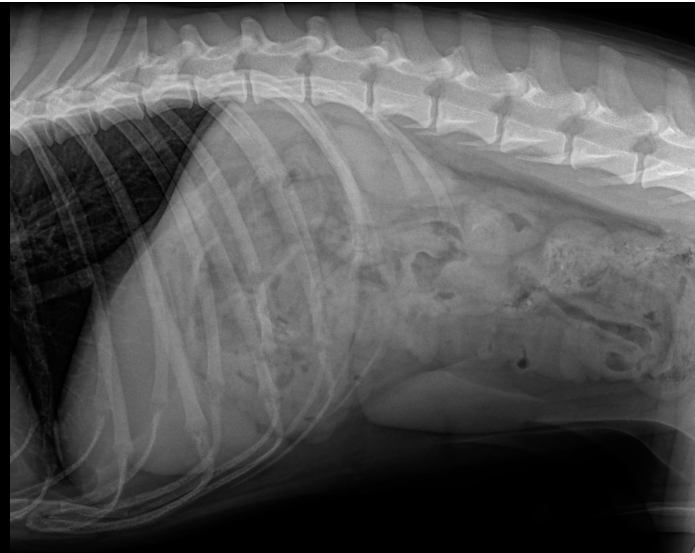

Manny, GS, MI, 1 year

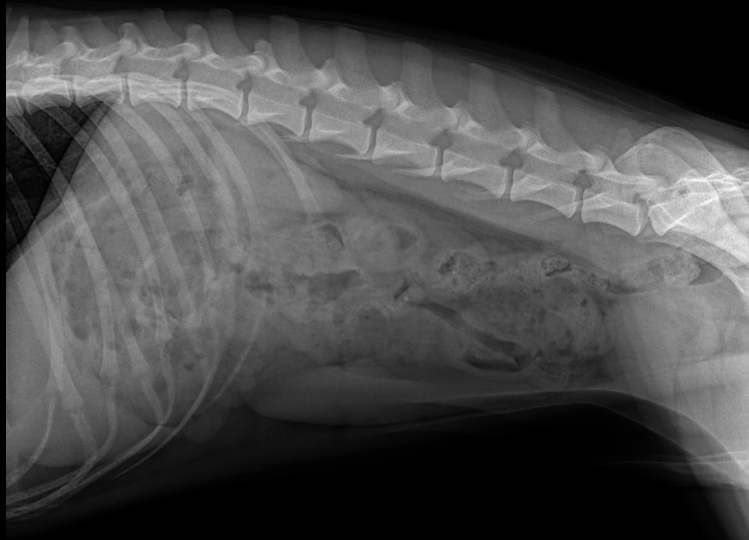- Vomiting numerous times starting today
- Abdominal pain with vocalisation



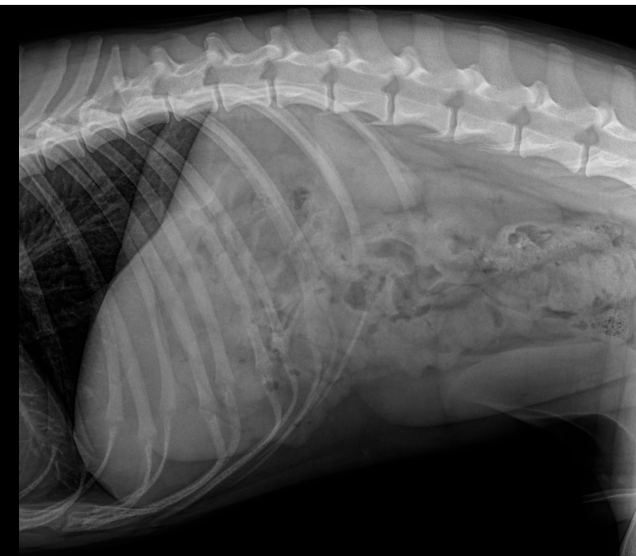
Manny, MI, 1 year

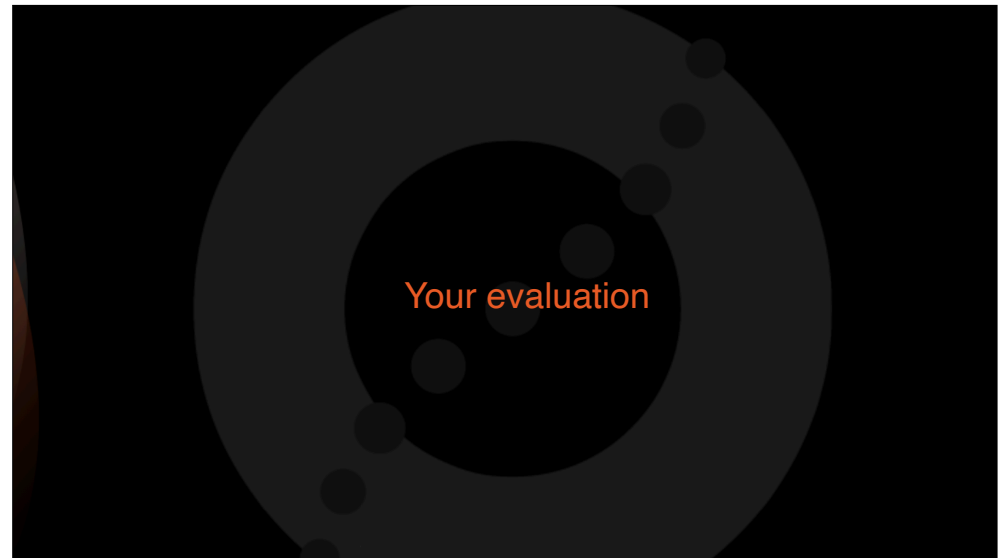
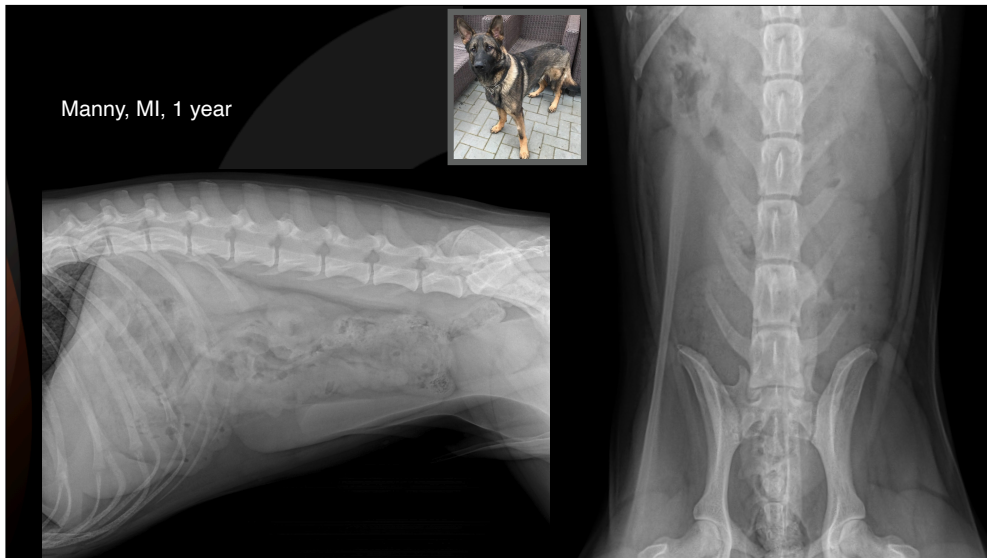
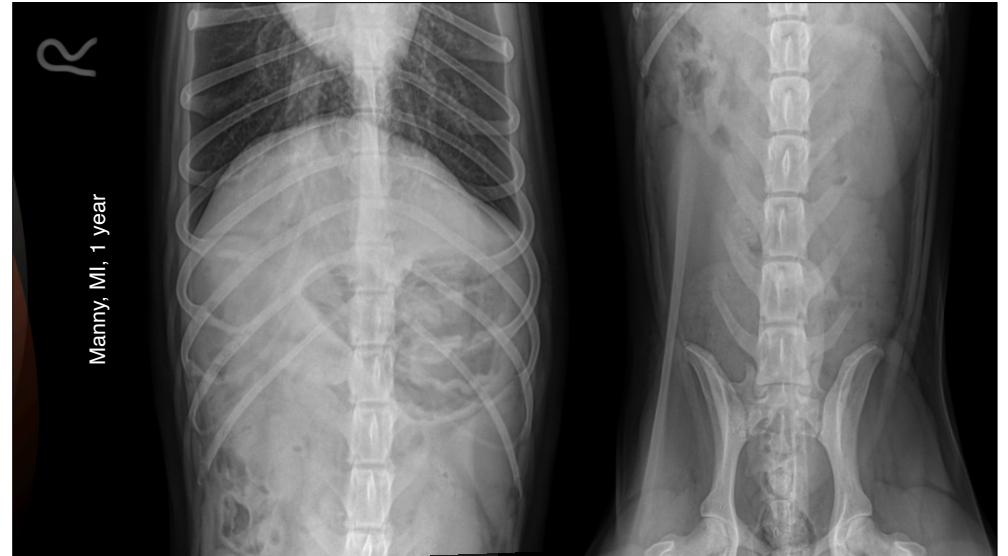
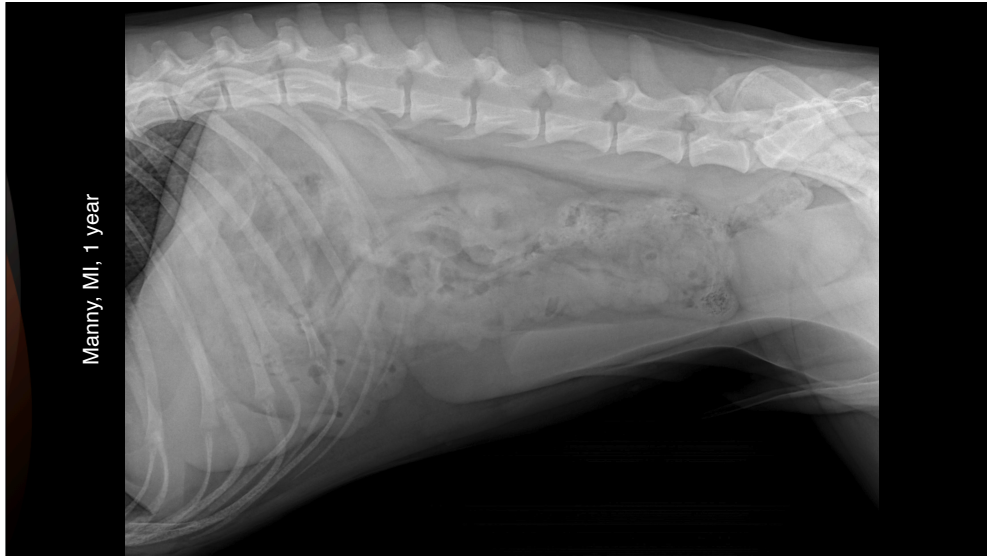
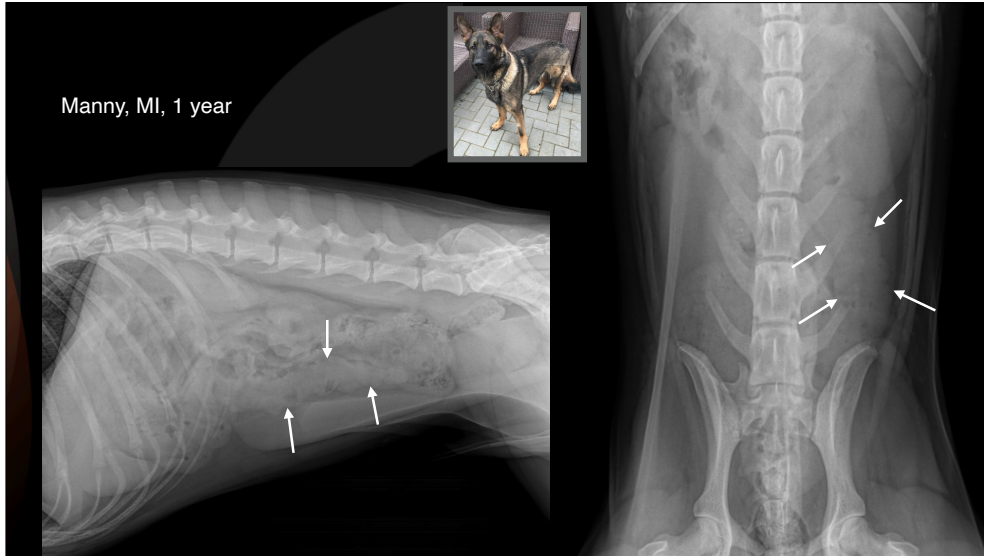
Manny, MI, 1 year



Manny, MI, 1 year







Manny, GS, MI, 1 year

Radiographic diagnoses:

- Severe plication of the SI

Conclusions

- A towel was removed at surgery (pylorus-jejunum)

Willy, Miniature Schnauzer, MI, 11 years

- Acute abdomen
- Not walking

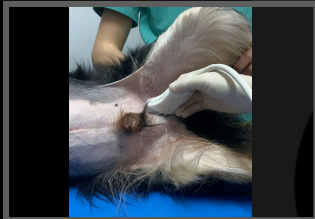Willy, MI, 11 years

Probe position

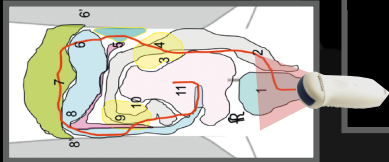
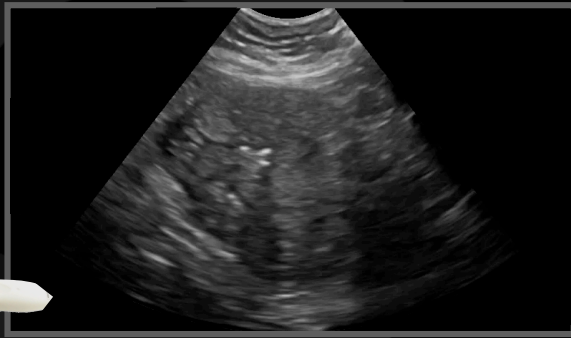Position 1

Willy, MI, 11 years

Probe position

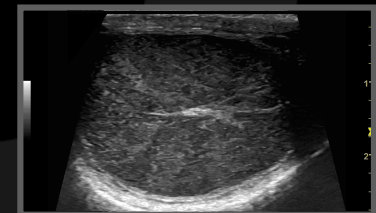
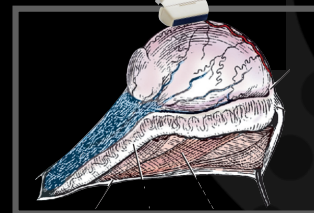
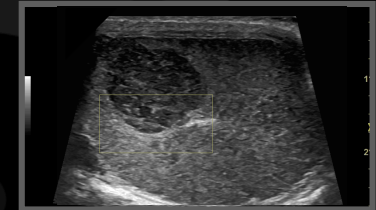
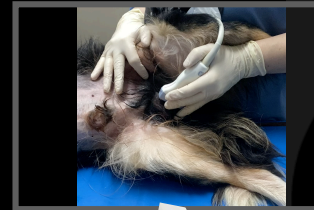


Position 1



Willy, MI, 11 years

Probe position



Willy, Miniature Schnauzer, MI, 11 years

Ultrasonographic diagnoses:

- Mineralised prostatopathy
- Nodular and generalised testicular disease



ORIGINAL ARTICLE

Prostatitis and prostatic abscessation in dogs: retrospective study of 82 cases

Australian Veterinary Journal Volume 100 No 6, June 2022

C Lea,^{a*} D Walker,^b CA Blazquez,^c O Zaghoul,^d S Tappin^e and D Kelly^a

Results A total of 82 dogs were included, and the median age was nine years. Acute prostatitis was diagnosed in 63% of cases, chronic prostatitis in 37% of cases and 40% of cases had prostatic abscessation. Prostatomegaly was the most common ultrasonographic finding. Mineralisation was identified in 20% of cases. The results of urine and prostatic bacterial culture were concordant in only 50% of cases. Antimicrobial resistance was encountered commonly, with 29% of cultures resistant to one antimicrobial and 52% resistant to two or more antimicrobials. Abscesses were from samples from the prostate. Sampling of the prostate is required to confirm a diagnosis and exclude other pathologies such as neoplasia, particularly as mineralisation is seen in a reasonable number of cases of dogs with prostatitis.

Willy, Miniature Schnauzer, MI, 11 years

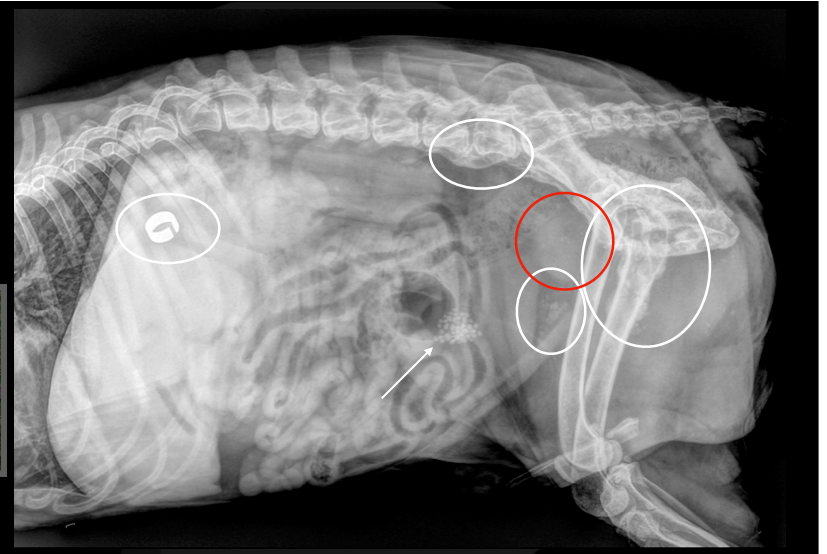
Ultrasonographic diagnoses:

- Mineralised prostatopathy
- Nodular and generalised testicular disease

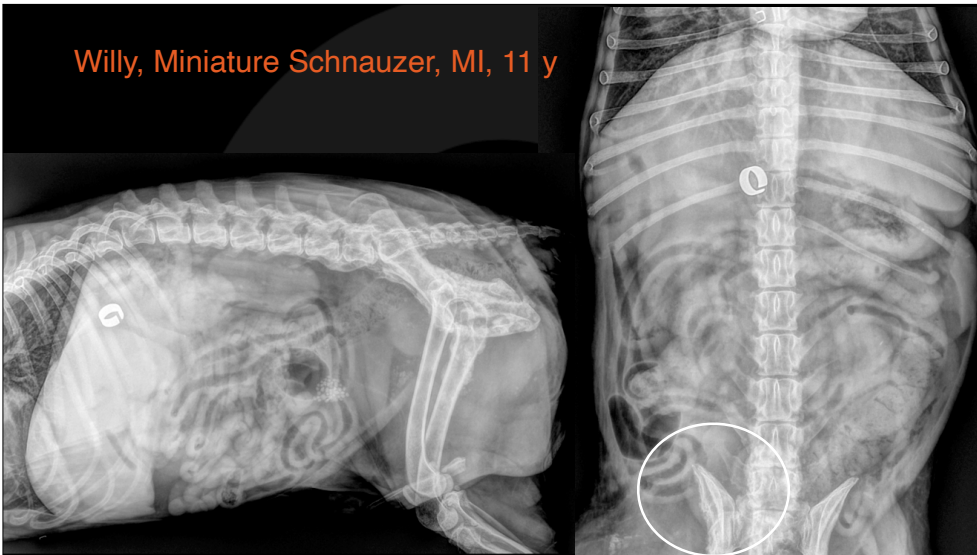


What next?

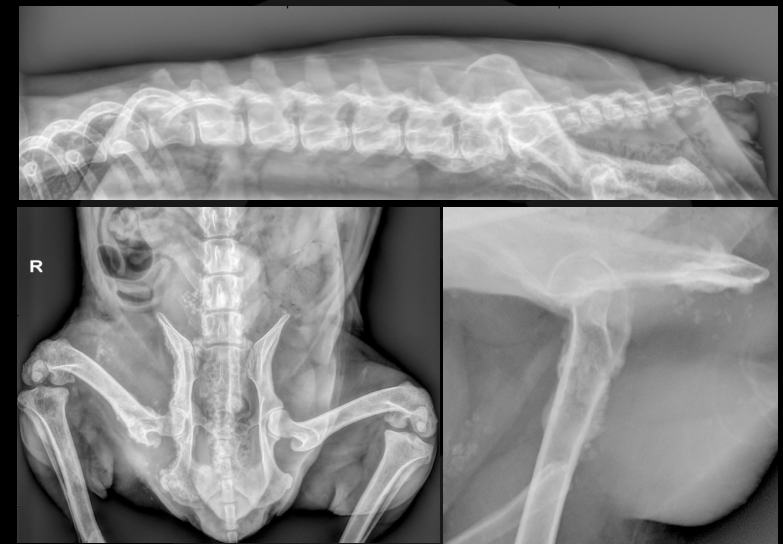Willy, MI, 11 years



Willy, Miniature Schnauzer, MI, 11 y

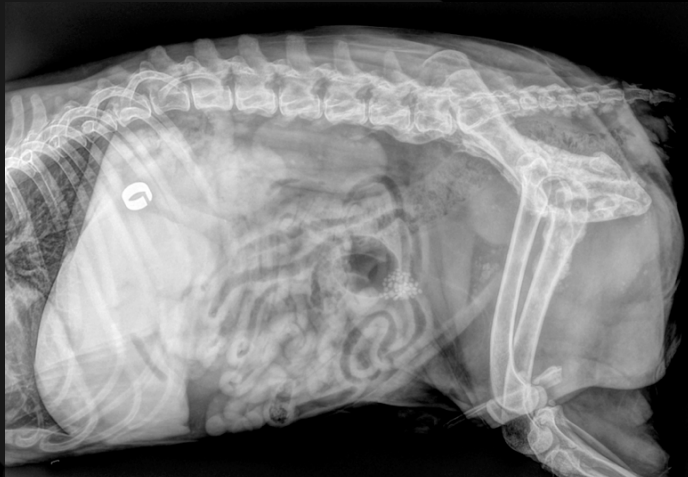

Willy, MI, 11 years



Metastatic path of canine prostatic cancer


- Continuity
- Lymphatic
- Venous



Willy, Miniature Schnauzer, MI, 11 years

Follow up

- Confirmed prostatic carcinoma
- Metastasis to the adjacent pelvic and femoral bones
- Metastasis to the surrounding peritoneum



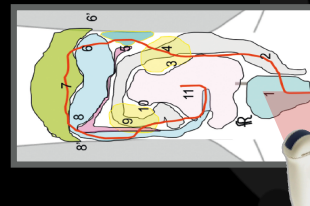
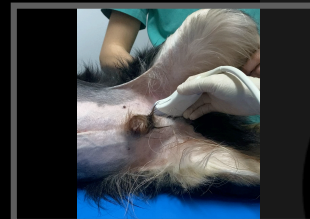
Nutella, Border Collies, MI, 6 years

- IMHA
- Treatment started two weeks ago
- Now sick again

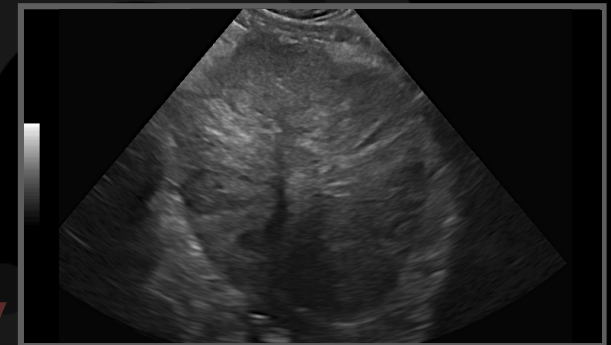


Nutella, MI, 11 years

Probe position



Position 1



Nutella, Border Collies, MI, 6 years

Ultrasonographic diagnoses:

- Prostatopathy
- Reactive surrounding peritoneum



Suspected acute prostatitis, Ab started, still under immunodepressant to treat the IMHA

Nutella, Border Collies, MI, 6 years

One week later

- Worsening general condition
- Fever
- Stranguria

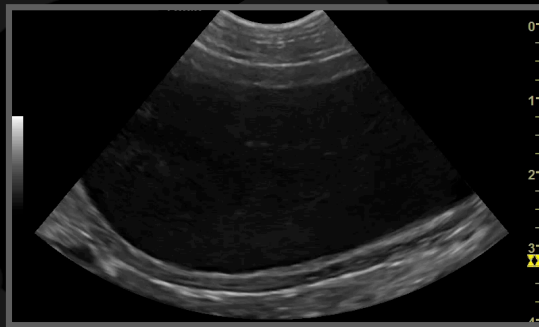
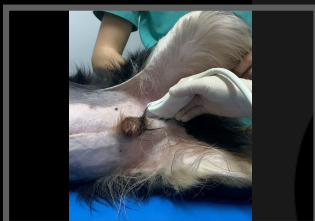
Nutella, MI, 11 years

Probe position

One week later

Position 1

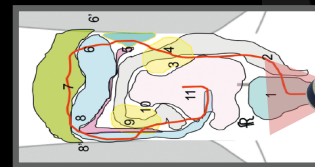
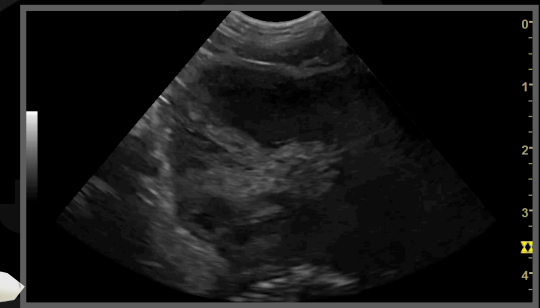
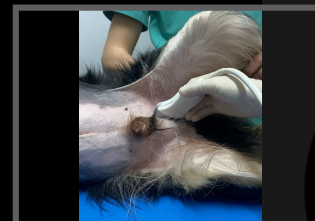
Nutella, MI, 11 years

Probe position

One week later

Position 1



Nutella, Border Collies, MI, 6 years

One week later

Ultrasonographic diagnoses:

- Prostatic cystic lesion
- Severely reactive surrounding peritoneum

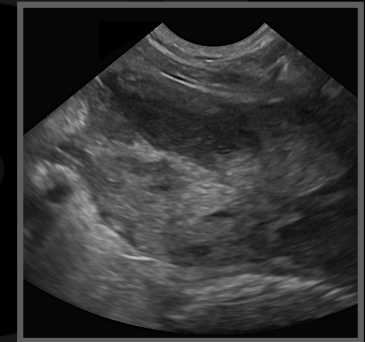


Suspected prostatic abscess, reduced immunodepressant to treat the IMHA

Nutella, Border Collies, MI, 6 years

Two weeks later

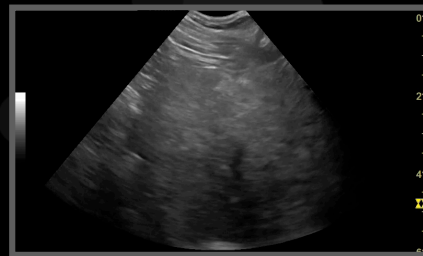- Back to normal clinically
- Still under AB
- No recurrence of IMHA



Nutella, Border Collies, MI, 6 years


Six weeks later

- Checking two weeks after AB discontinuation
- Unremarkable blood works

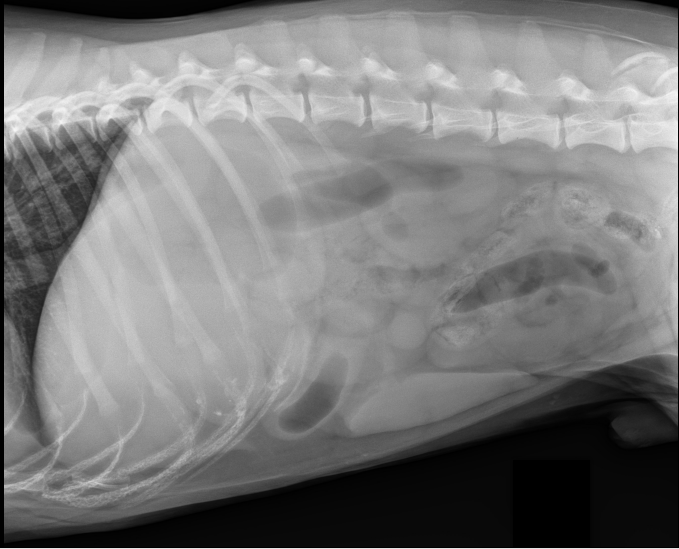


Beau, Mongrel, MN, 2 years

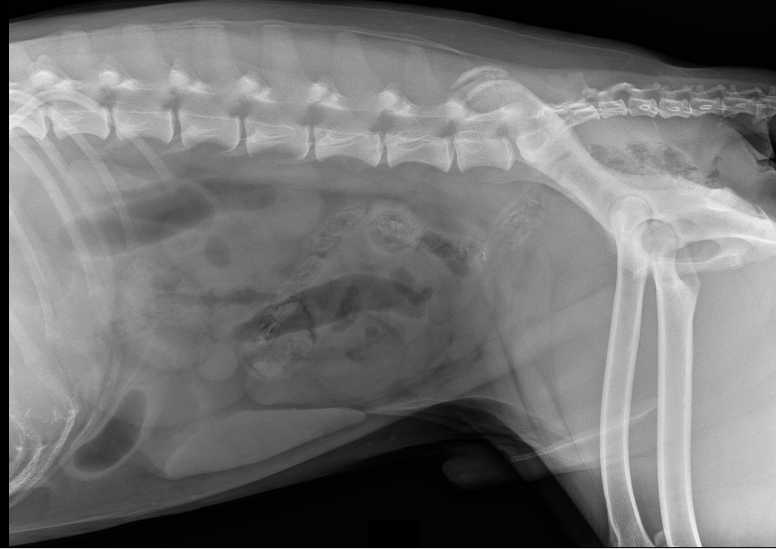
- Anorexic for three days
- Diarrhoea
- Now vomiting



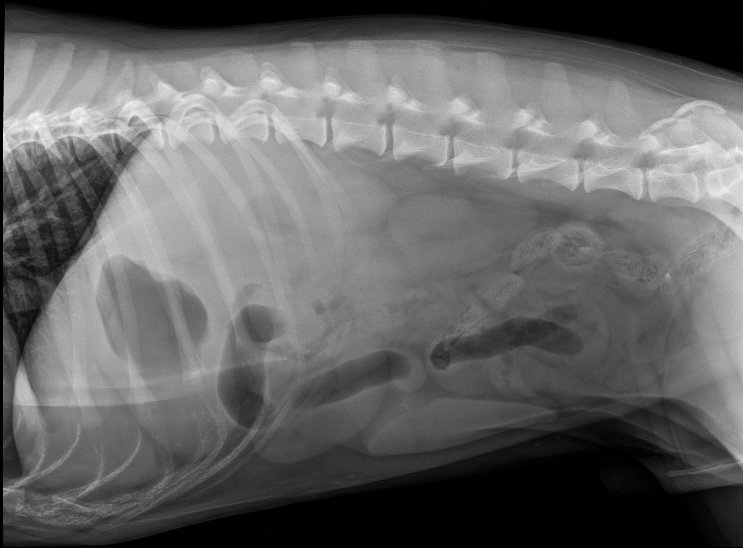Beau, MN, 2 years



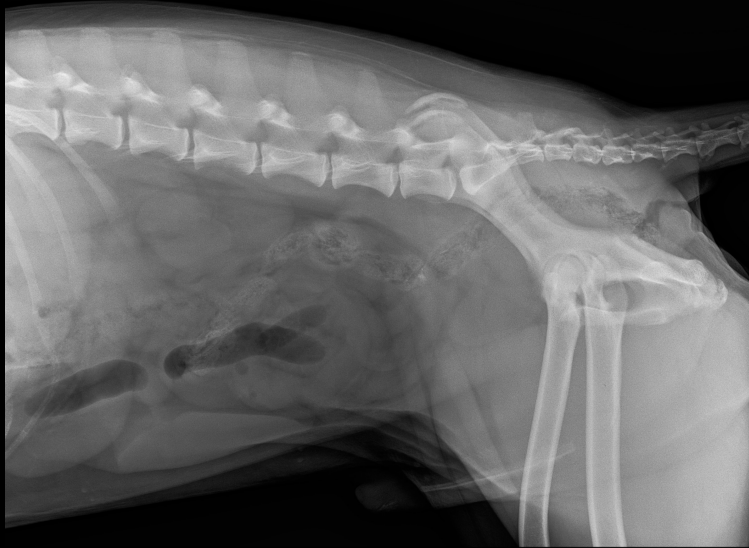
Beau, MN, 2 years



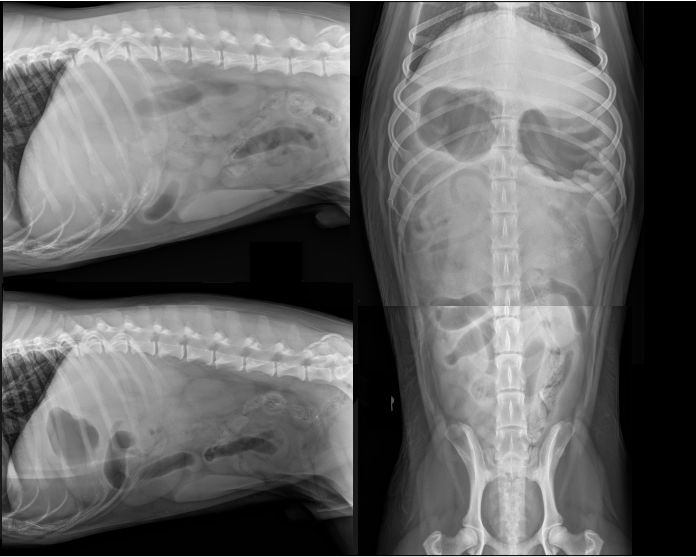
Beau, MN, 2 years



Beau, MN, 2 years

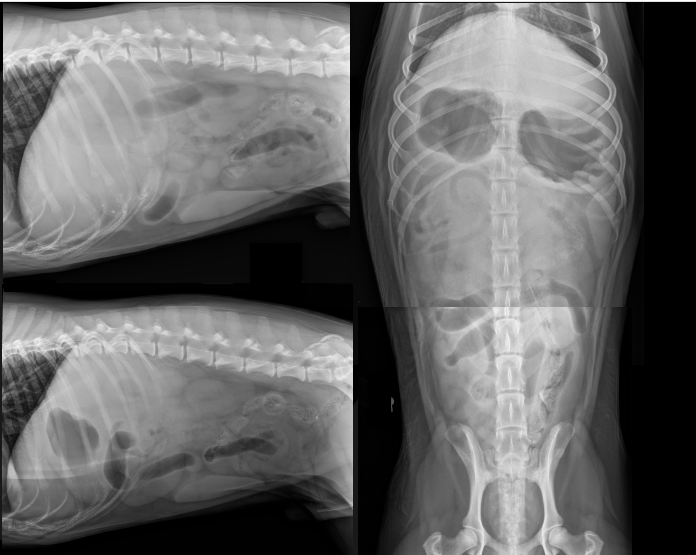


Beau, MN, 2 years



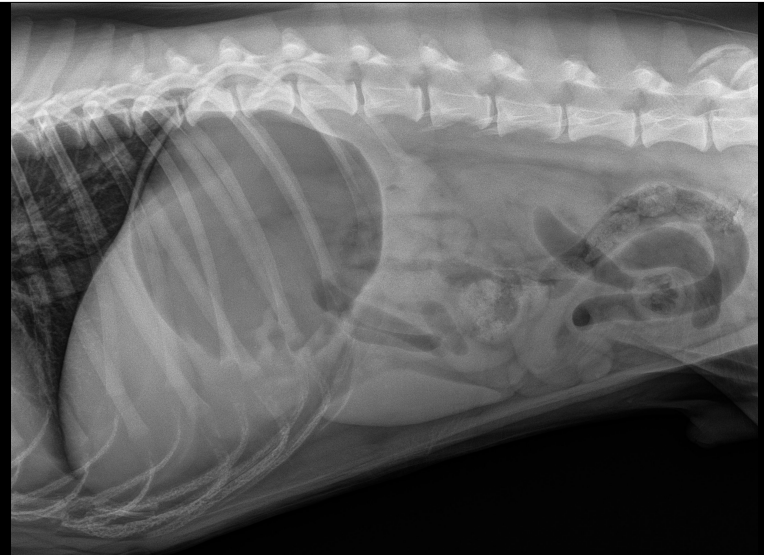Your evaluation?

Beau, MN, 2 years

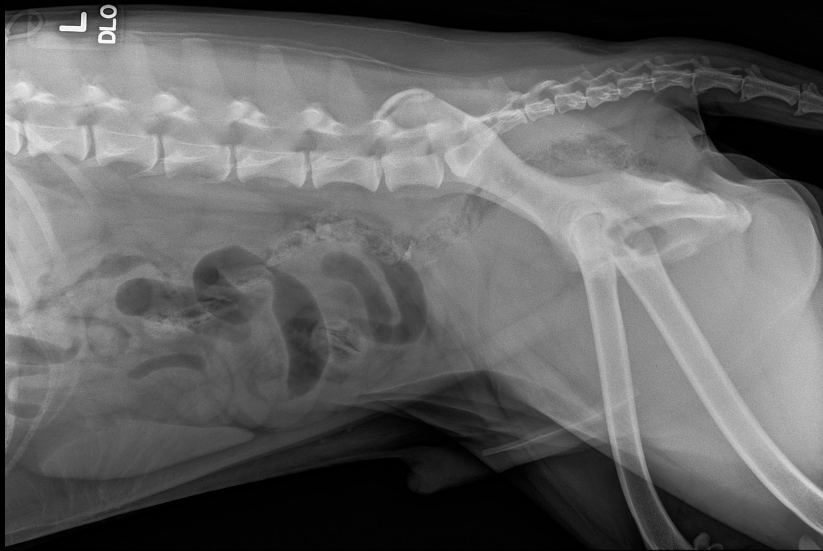

Beau, MN, 2 years

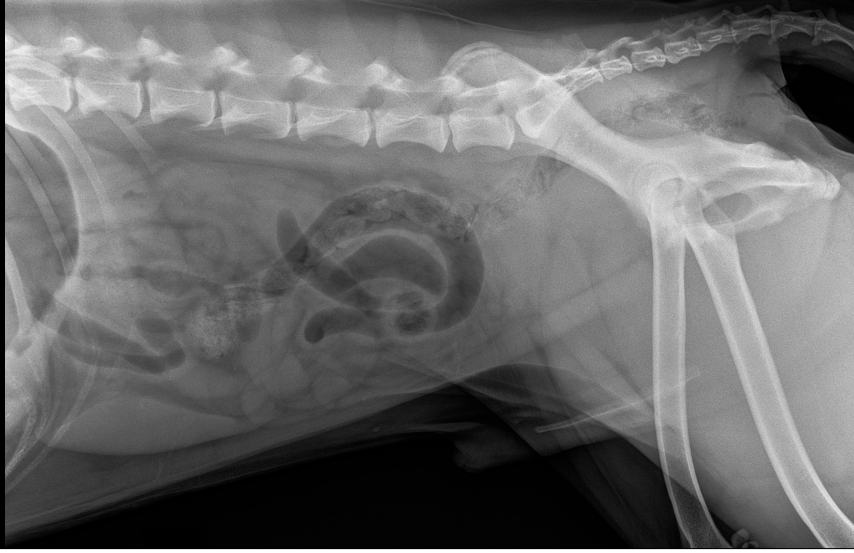24 hours later, still anorexic



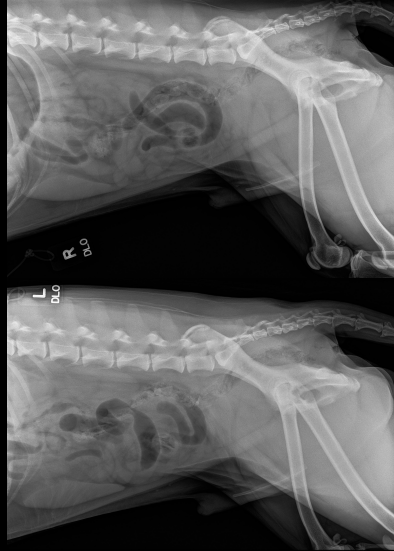
Beau, MN, 2 years
24 hours later, still anorexic



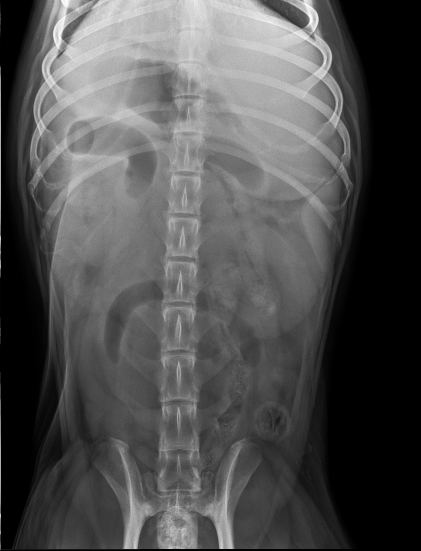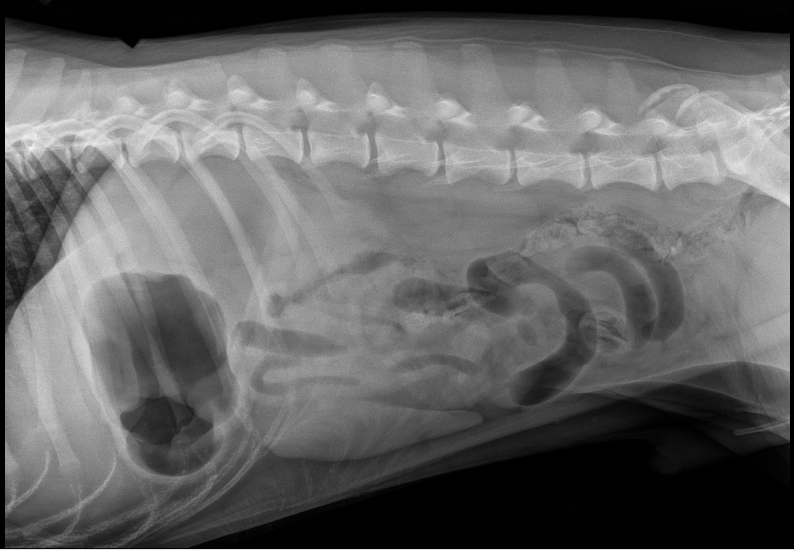
Beau, MN, 2 years
24 hours later, still anorexic



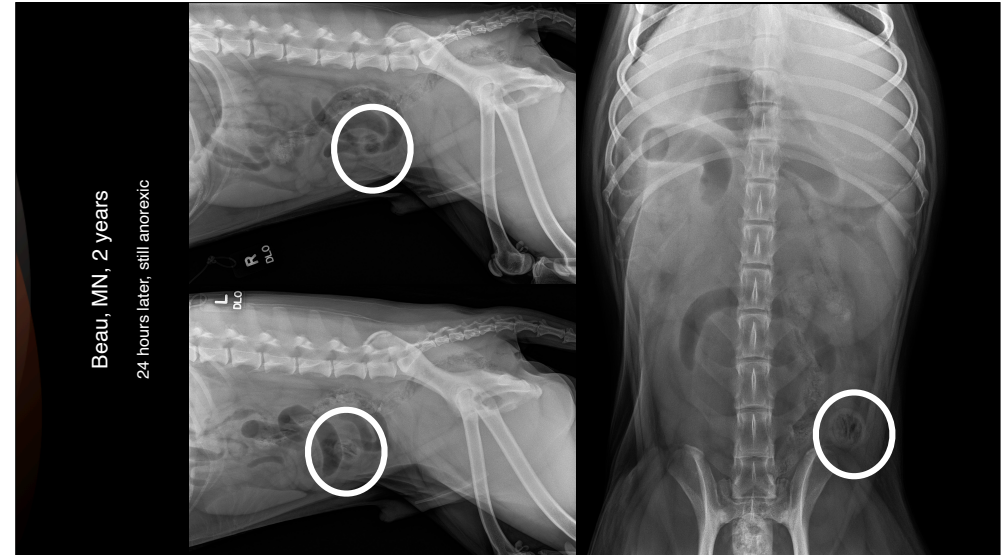
Beau, MN, 2 years
24 hours later, still anorexic



Beau, MN, 2 years
24 hours later, still anorexic




Your evaluation?



Beau, Mongrel, MN, 2 years

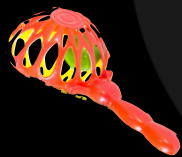
Radiographic diagnoses:

- Mechanical SI occlusion by FB



Conclusions

- Surgical removal of the FB



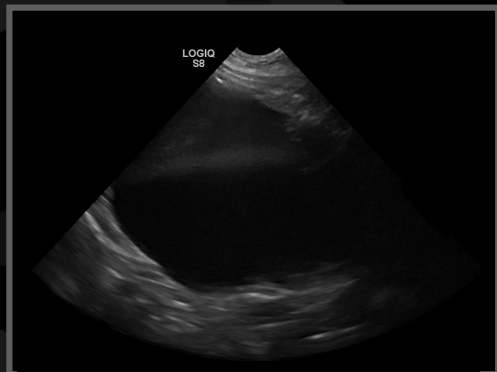
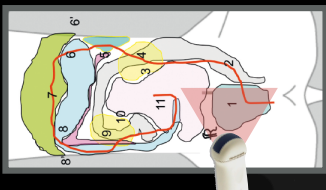
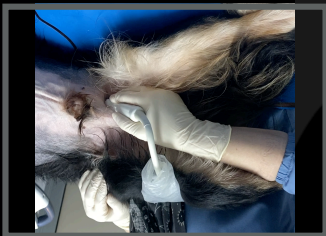Thor, Neapolitan Mastiff, MI, 6 years

- Acute vomiting
- Not playing with the other two puppies
- Attempt to defecate, not successful
- Cryptorchid



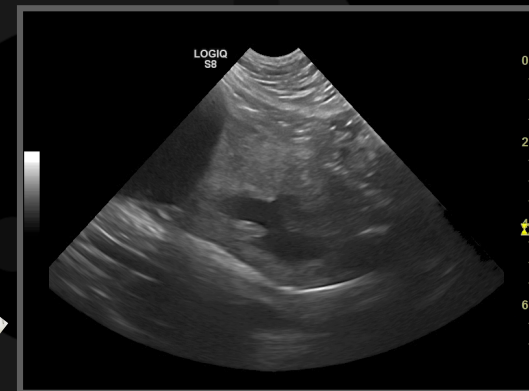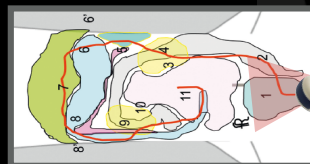
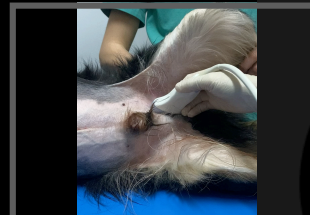
Thor, MI, 6 years

Probe position in a different patient



Thor, MI, 6 years

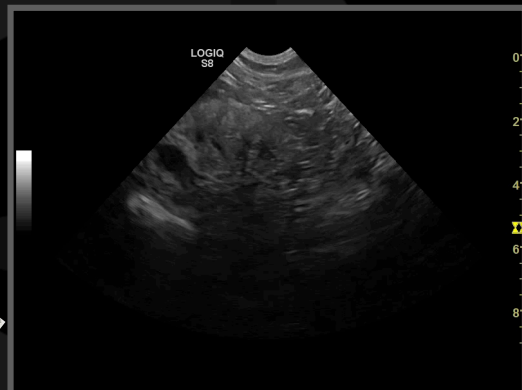
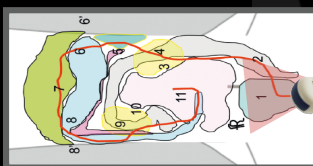
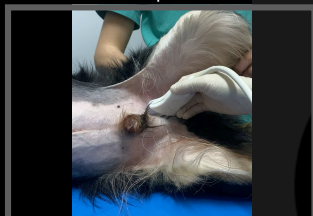
Probe position



Position 1

Thor, MI, 6 years

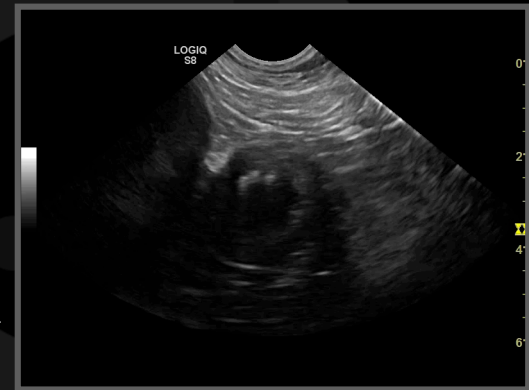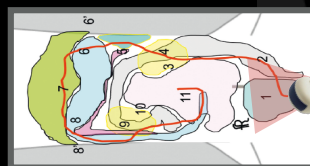
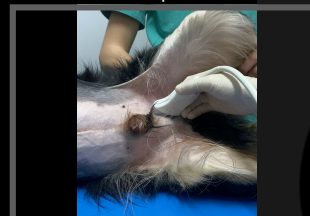Probe position



Position 1

Thor, MI, 6 years

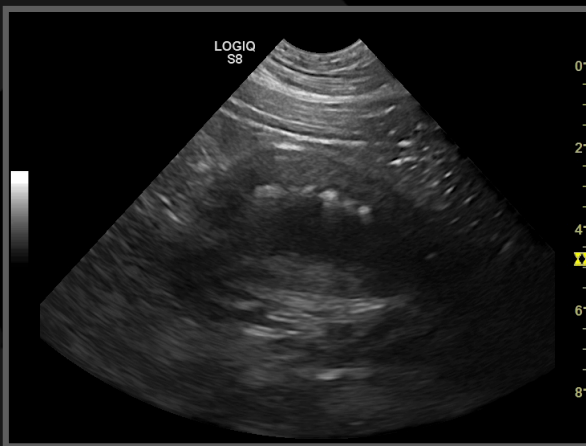
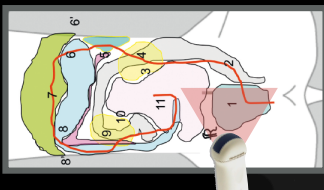
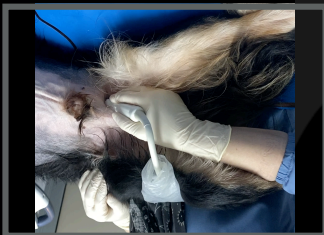Probe position



Position 1

Thor, MI, 6 years

Probe position in a different patient



Thor, Neapolitan Mastiff, MI, 6 years

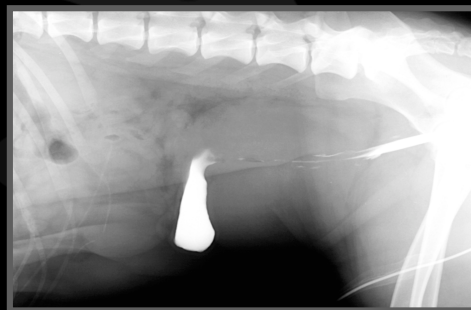
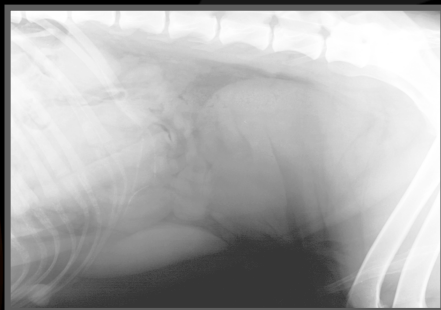
Ultrasonographic diagnoses:

- Paraprostatic cyst?
- Intraprostatic cysts?
- Urinary stones?



What next?

Thor, Neapolitan Mastiff, MI, 6 years



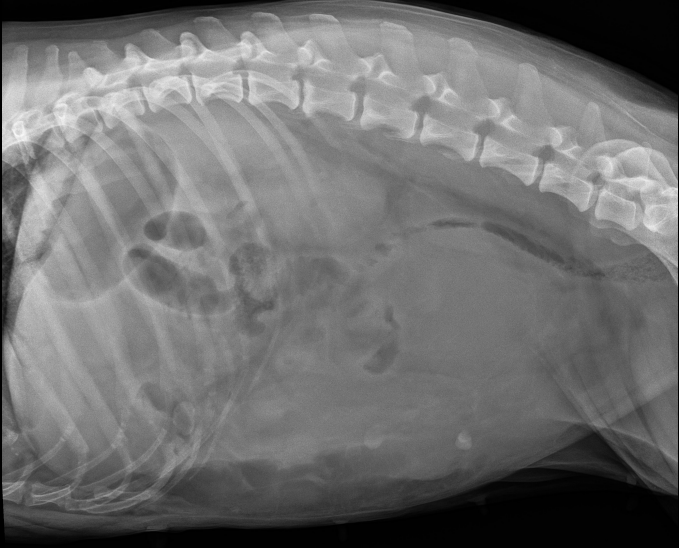Follow up: peritoneal omentalization of the paraprostatic cyst

Rita, Brittany, FI, 4 years

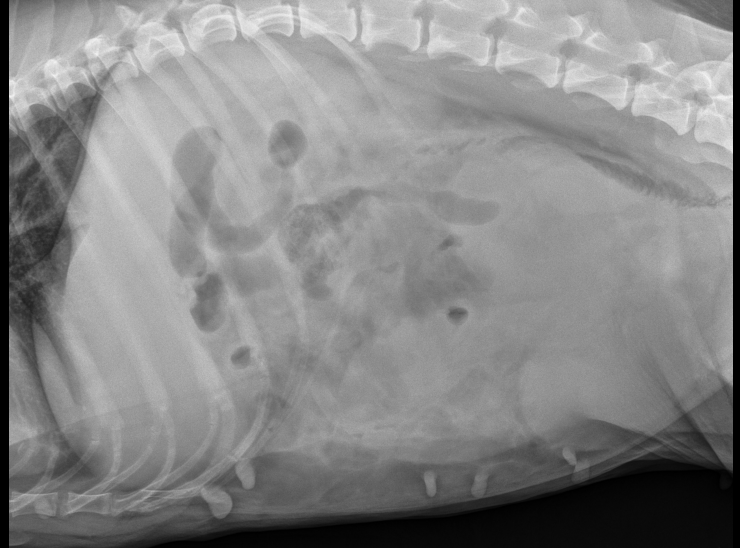- Presented in lateral recumbency
- Hypoglycaemia



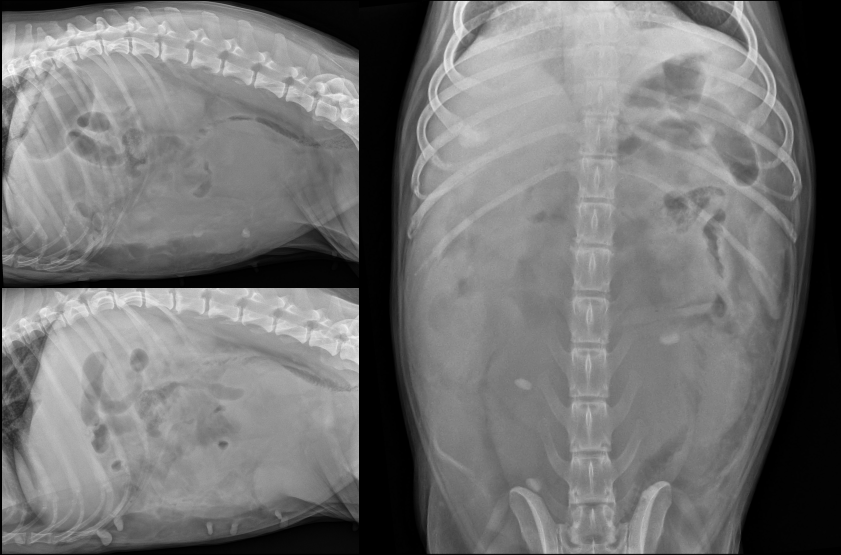
Rita, Fl, 4 years



Rita, Fl, 4 years

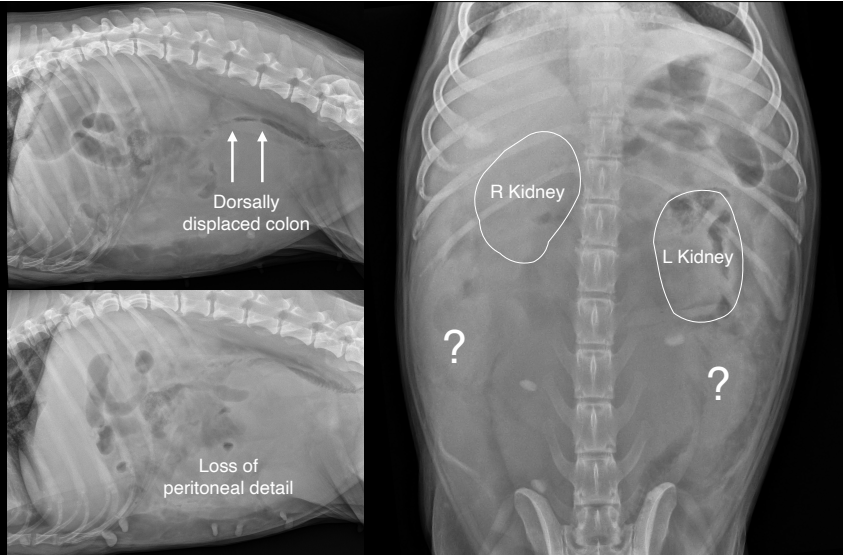


Rita, Fl, 4 years



Your evaluation?

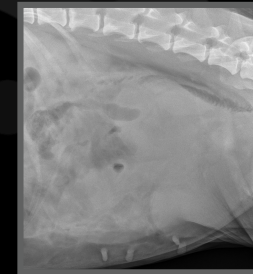Rita, FI, 4 years



Rita, Brittany, FI, 4 years

Radiographic diagnoses:

- Focal loss of abdominal detail
- Tubular structure

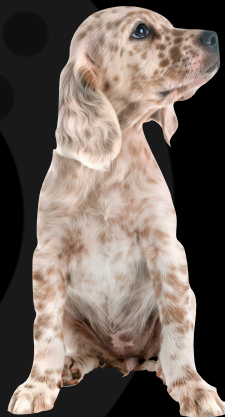

Conclusions

- Pyometra confirmed on US. Treated once stable, recovered

Basco, English Setter, MI, 3 Months

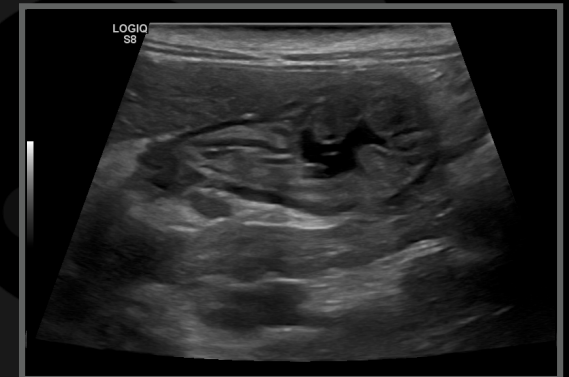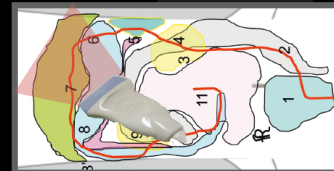
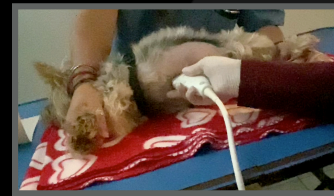- Acute vomiting
- Not playing with the other two puppies
- Attempt to defecate, not successful
- Cryptorchid



Basco, MI, 3 Months

Probe position in a different patient

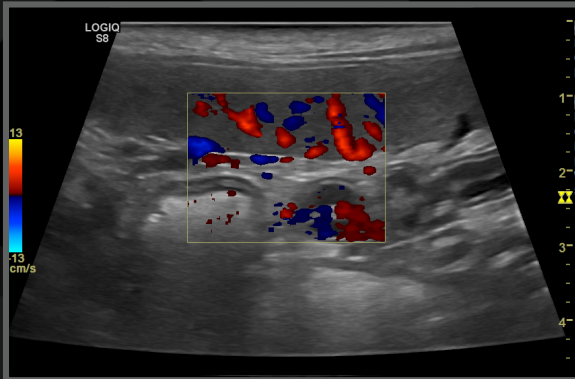
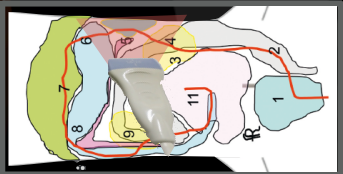
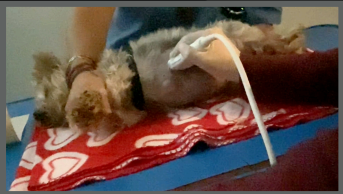7-6



Basco, MI, 3 Months

Probe position in a different patient

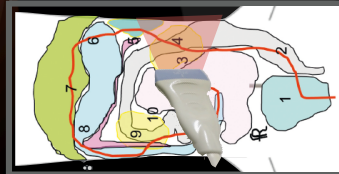
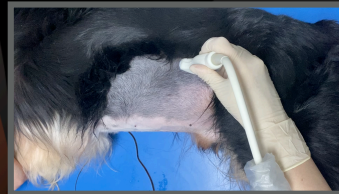5



Basco, MI, 3 Months

Probe position in a different patient

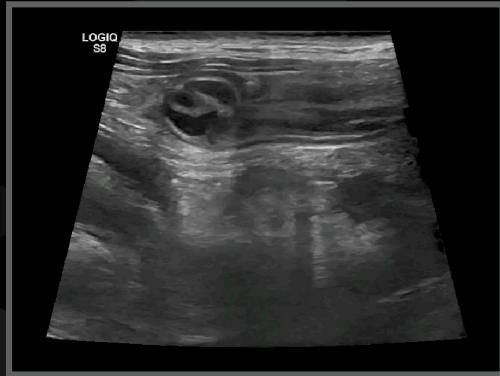
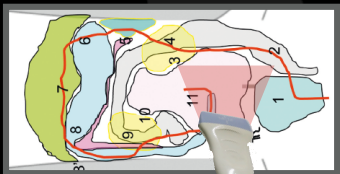
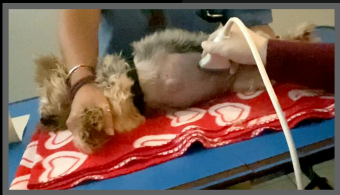5-4



Basco, MI, 3 Months

Probe position in a different patient

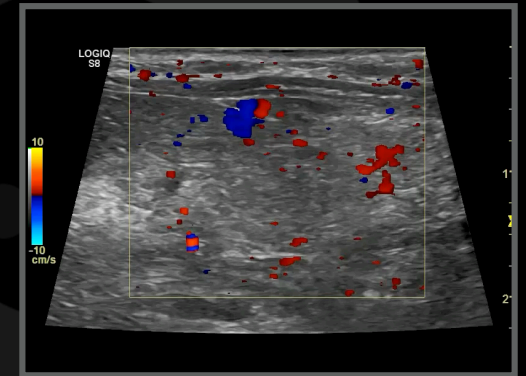
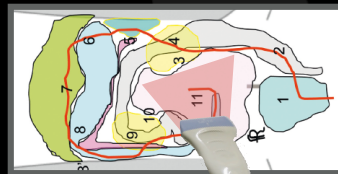
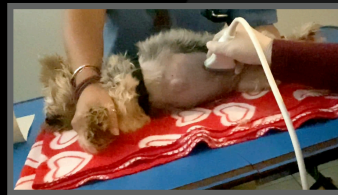10-11

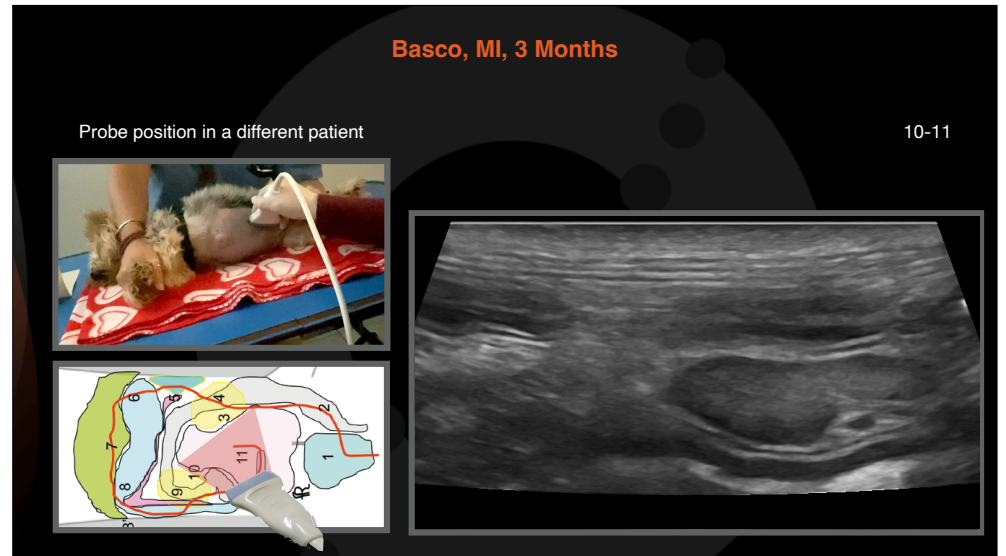
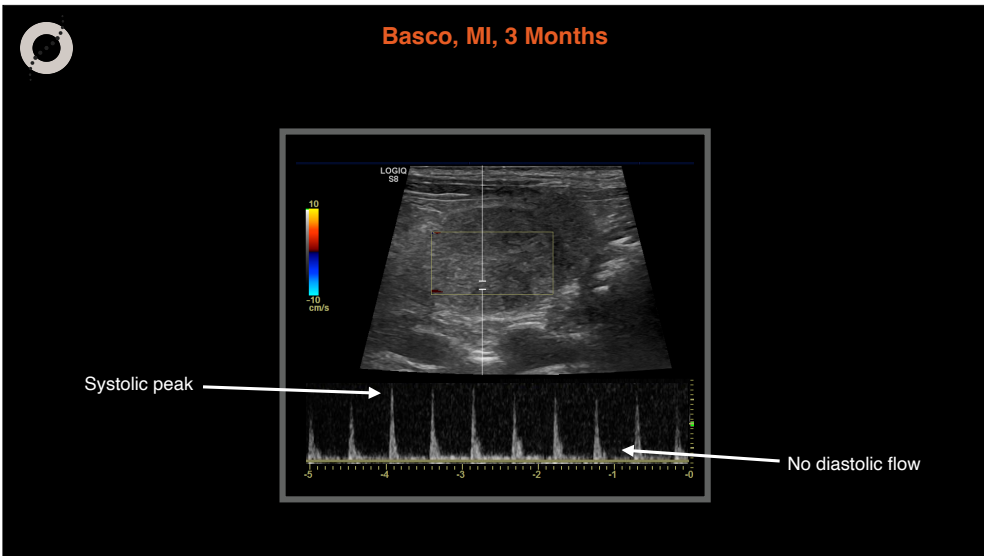
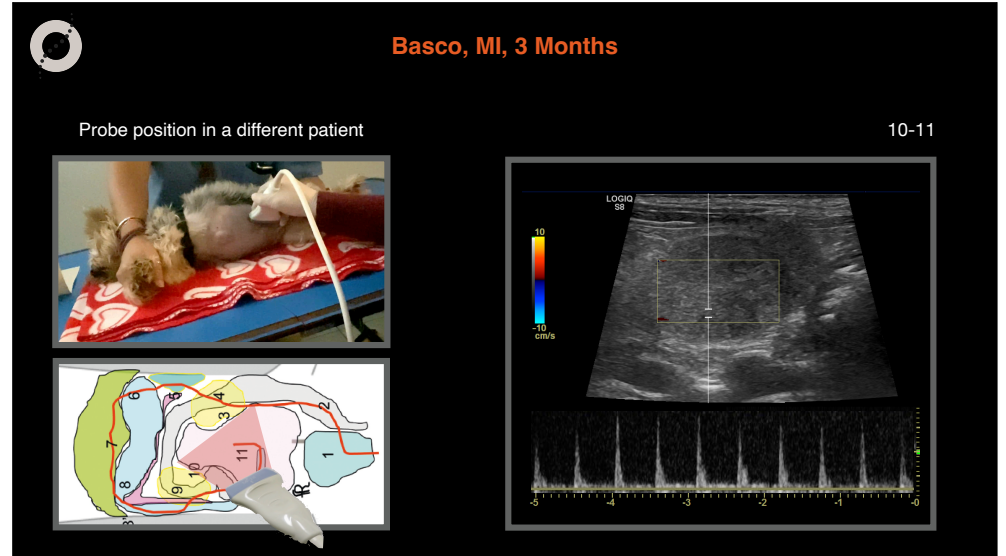
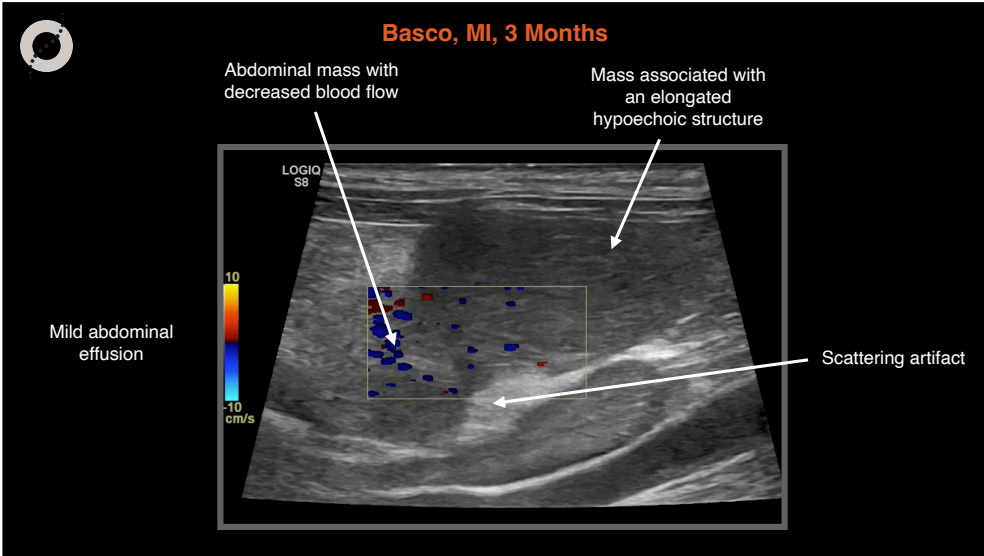


Basco, MI, 3 Months

Probe position in a different patient

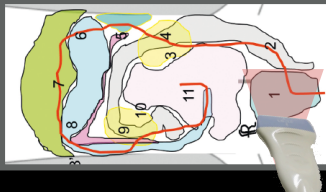
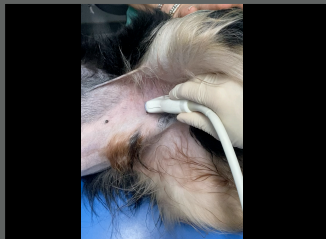
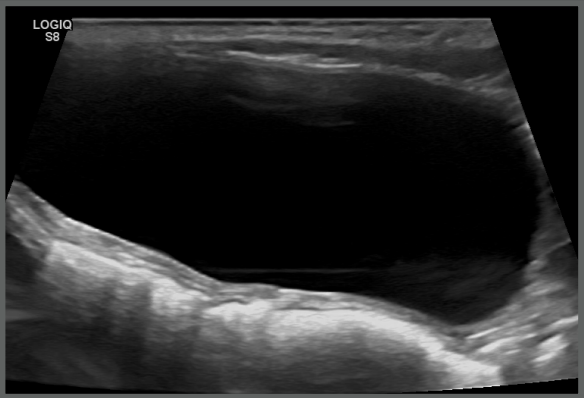
10-11





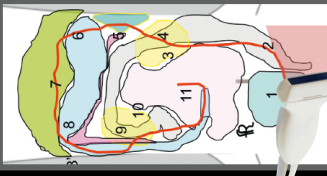

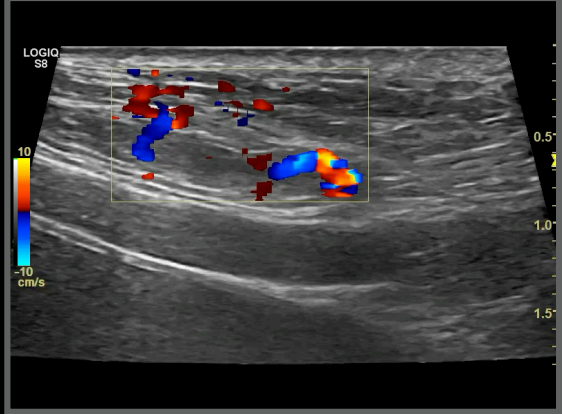
Basco, MI, 3 Months 1

Probe position in a different patient



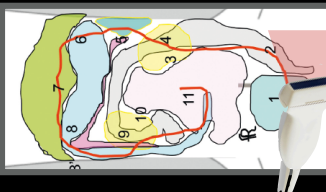

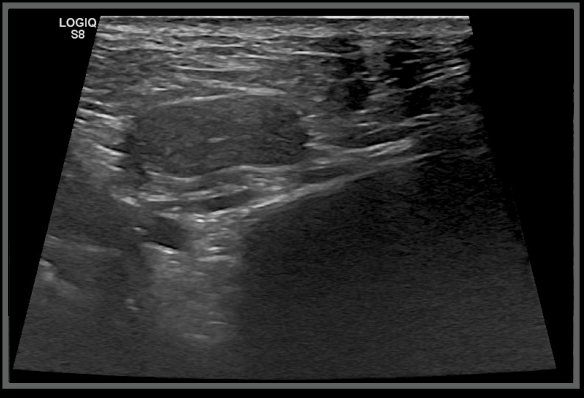
Basco, MI, 3 Months 0

Probe position in a different patient



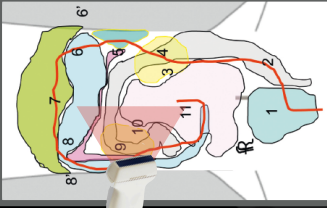

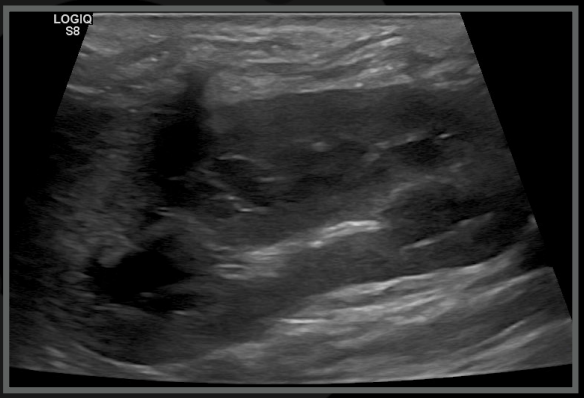
Basco, MI, 3 Months 0

Probe position in a different patient



Basco, MI, 3 Months 9

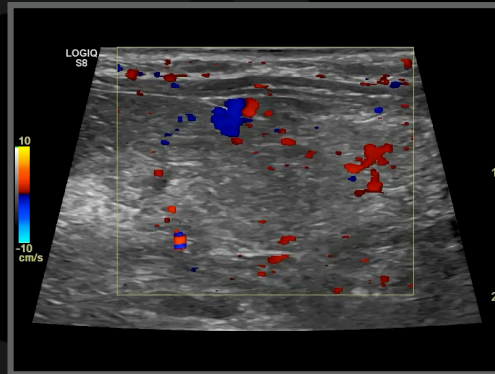
Probe position in a different patient



Basco, English Setter, MI, 3 Months

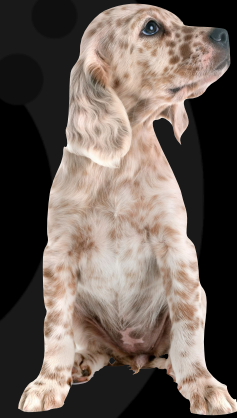Ultrasonographic diagnoses:

- Poor vascularisation of retained right testicle
- Focal scattering artefact
- Torsional Doppler
- Para-prepuzial left testicle



How to arrive at Conclusions:

- PE examination
- Blood works
- Ultrasonographic findings
- Literature



The screenshot shows a PubMed search results page for the query "testicular torsion dog". The search results are sorted by "Best match" and show 48 results. The first result is "Computed tomography of testicular torsion in a juvenile dog with unilateral cryptorchidism" by Slaughter SA, Eitzer AD, Tolliver SE, Holman SN, Colopy SA, Hoey SE, Loeber SJ, published in *Clin Vet J* 2022 May;63(5):515-520. The second result is "Testicular torsion in the dog: a review of 13 cases" by Pearson H, Kelly DF, published in *Vet Rec* 1975 Sep 13;97(11):200-4. The third result is "Testicular torsion in the dog" by Henney JR, published in *Vet Rec* 1980 Nov 22;107(21):495. The fourth result is "Testicular torsions in veterinary medicine" by Raisi A, Davoodi F, published in *Vet Res Commun* 2022 Jun;46(2):303-313.

Case Report Rapport de cas

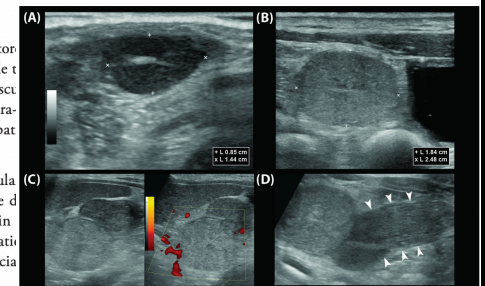
Can Vet J 2022;63:515-520

Computed tomography of testicular torsion in a juvenile dog with unilateral cryptorchidism

Sarah A. Slaughter, Andrew D. Eitzer, Sara E. Tolliver, Sarah N. Holman, Sara A. Colopy, Seamus E. Hoey, Samantha J. Loeber

Abstract – A 14-week-old male unilaterally cryptorchid examination revealed abdominal pain, and a single testis. Computed tomography (CT) revealed a poorly vascularized testis with scant regional peritoneal effusion. Left intraroutine cryptorchidectomy was performed. The patient recovered well.

Key clinical message:
The most common CT characteristics of testicular torsion are a poorly vascularized testis, scant regional peritoneal effusion, and a single testis. Ultrasonographic findings to allow for rapid, accurate diagnosis of intra-abdominal cryptorchid testicular torsion in localization of the undescended testis and evaluation of testicular blood flow are discussed. Ultrasonography is a valuable tool for diagnosing testicular torsion, especially in the presence of a single testis.



Effects of Unilateral Testicular Torsion on the Blood Flow of Contralateral Testis

An Experimental Study on Dogs

Scand J Urol Nephrol 34: 229-232, 2000

Fatih Tarhan, Mehmet Erkan Erbay, Erhan Erdoğan, Aydın Özgül and Uğur Kuyumcuoğlu

The effects of unilateral testicular torsion on the blood flow of the contralateral testis were investigated. Fourteen adult male dogs were recruited. Seven dogs underwent unilateral testicular torsion of 4 h duration, and the other seven dogs had a control operation. Testicular blood flow was determined by colour Doppler ultrasonography before and after the testicular torsion. Bilateral orchidectomy was performed at the end of the study and histopathological changes were evaluated. Values of peak systolic velocity, end diastolic velocity, and resistive index were not statistically significant between ipsilateral and contralateral testes in the study group ($p > 0.05$). On comparison with the control group, blood flow in the contralateral testes showed no statistically significant difference ($p > 0.05$). Oedema and congestion were seen on ipsilateral testes in the study group. No histopathological changes were noted on the contralateral testes. Minimal oedema and congestion secondary to manipulation were found in the control operation testes. We conclude that unilateral testicular torsion does not decrease contralateral testicular blood flow as shown by colour Doppler ultrasonography.

Basco, English Setter, MI, 3 Months

Conclusions:

- Strong suspicion of torsion of the right, retained, testicle
- Surrounding focal peritonitis

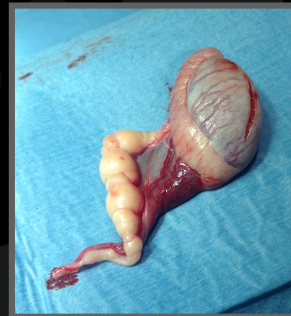
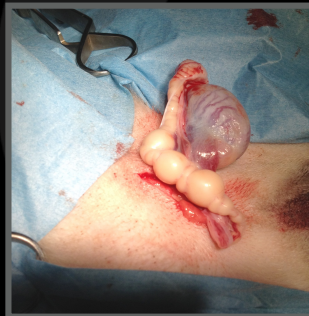Follow up

- Planned laparotomy



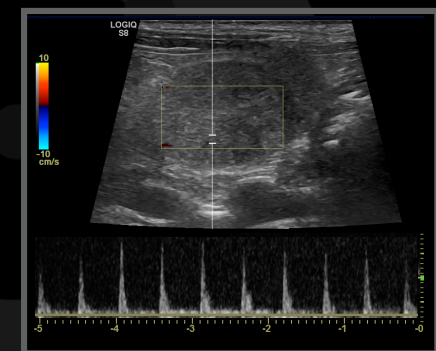
Basco, English Setter, MI, 3 Months

- Removed the twisted testicle
- Patient recovered in three days



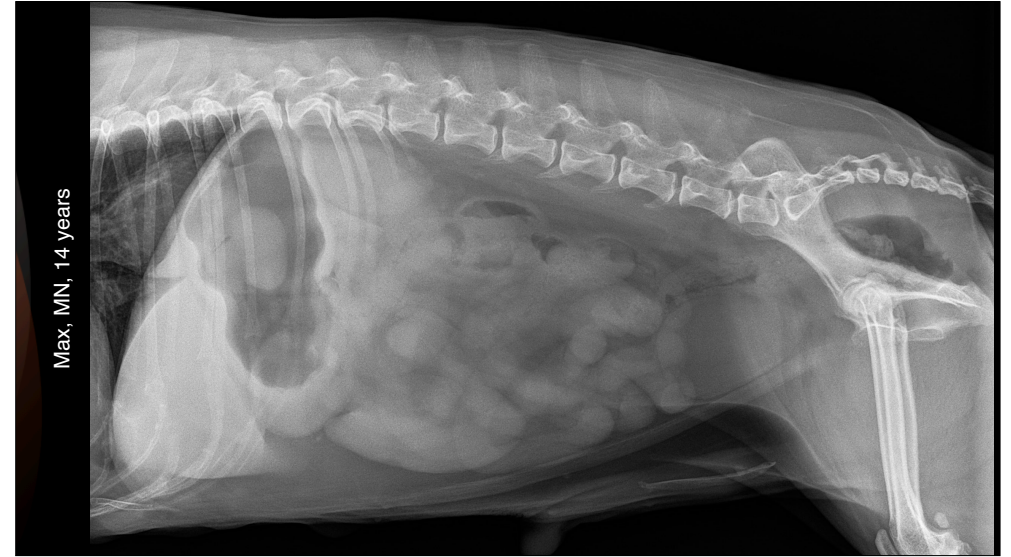
Key Points for testicular torsion

- Oval abdominal mass associated with an elongated hypoechoic structure
- Surrounding peritonitis
- Decreased blood flow in the mass
- +/- Torsional Doppler

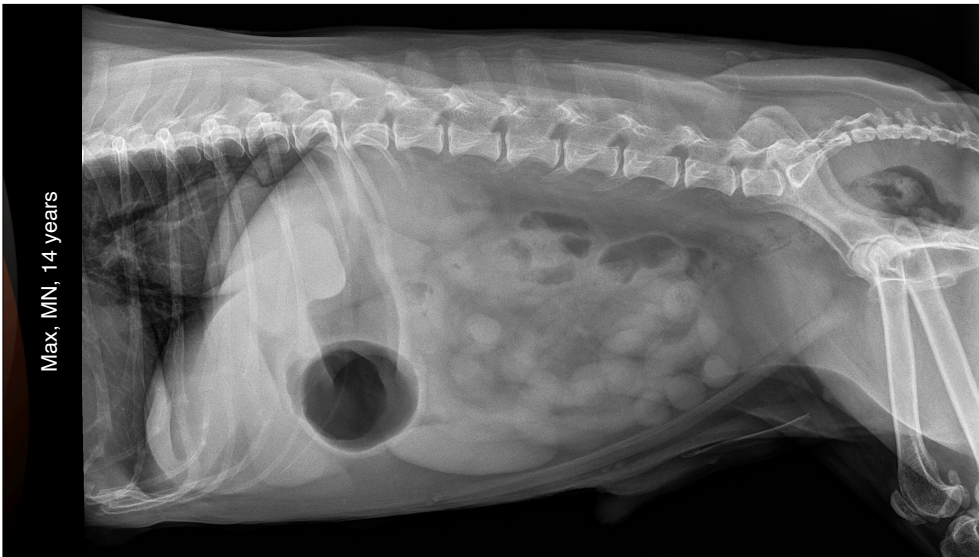


Max, Cairn Terrier, MN, 14 years

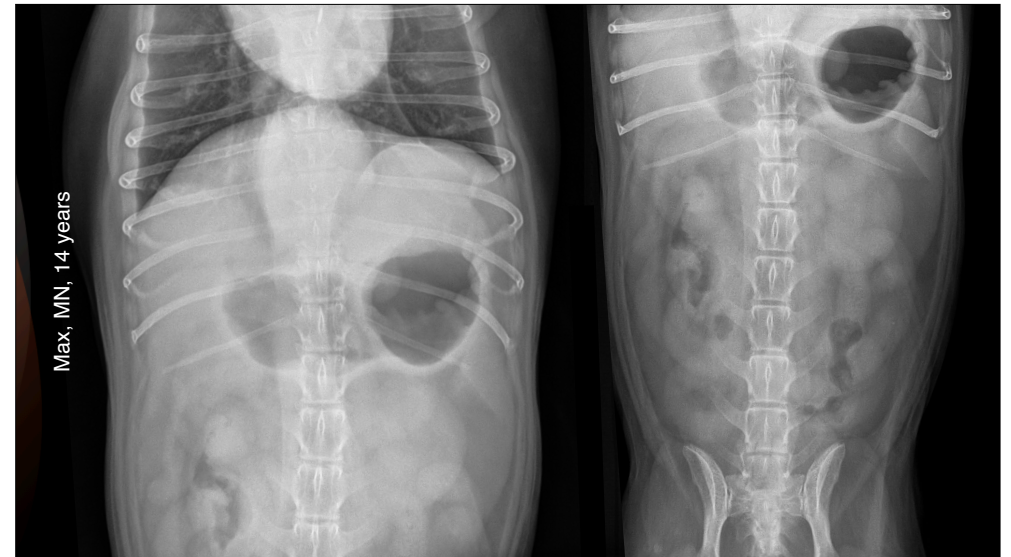
- Vomiting and anorexia
- Trembling episodes
- History of pancreatitis
- Soft brown stool on rectal examination



Max, MN, 14 years

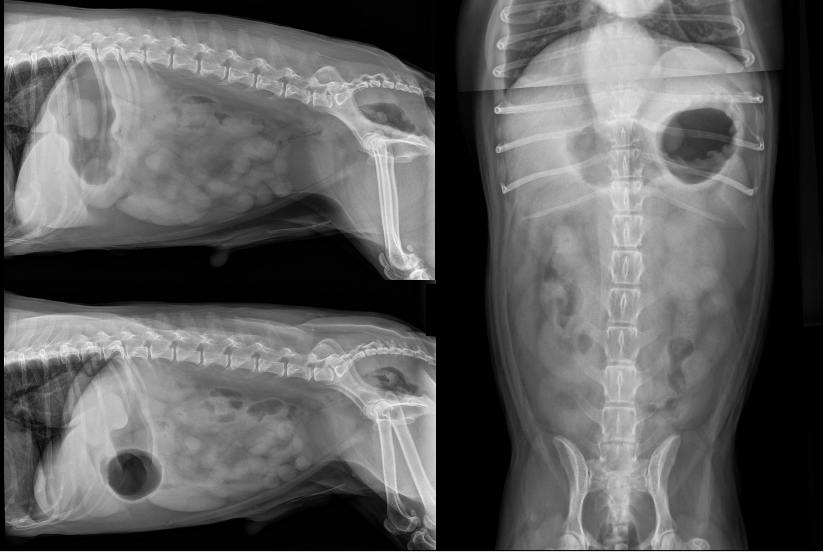


Max, MN, 14 years



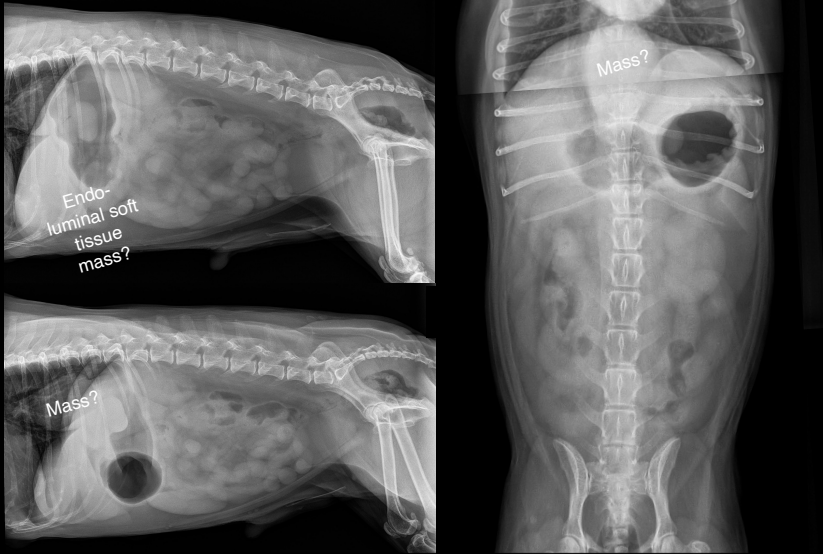Max, MN, 14 years

Max, MN, 14 years

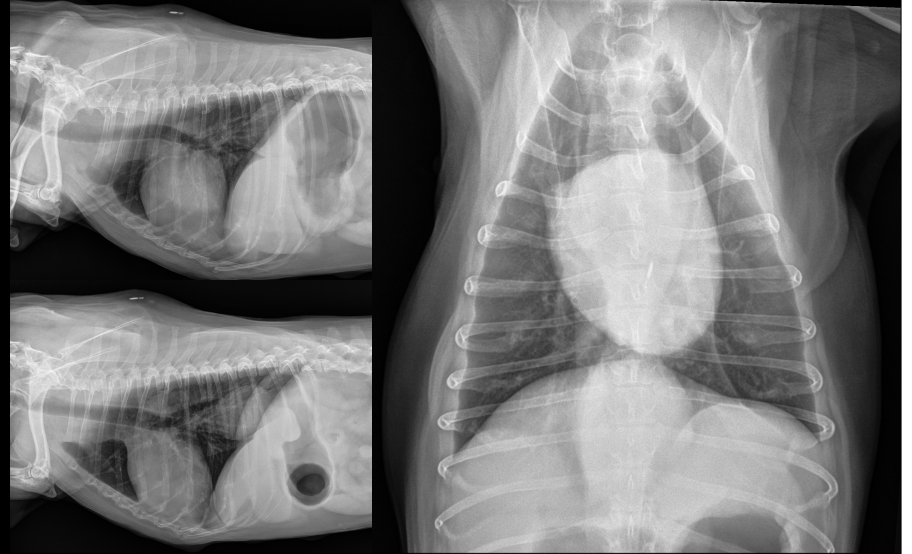

Your evaluation?

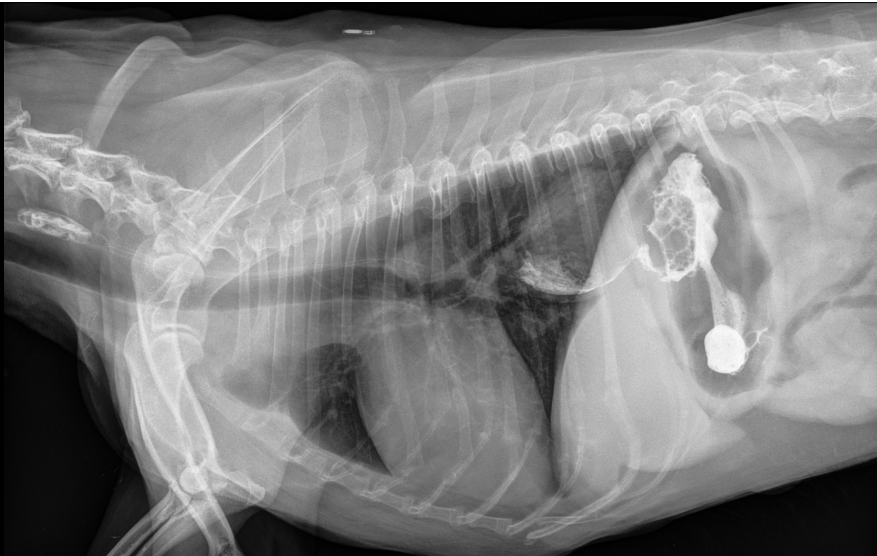Max, MN, 14 years



Max, MN, 14 years



Max, MN, 14 years



Max, Cairn Terrier, MN, 14 years

Radiographic diagnoses:

- Caudal oesophageal mass protruding in the gastric lumen

Conclusions

- Endoscopic sampling: adenocarcinoma



Newton, DSH, FI, 16 years

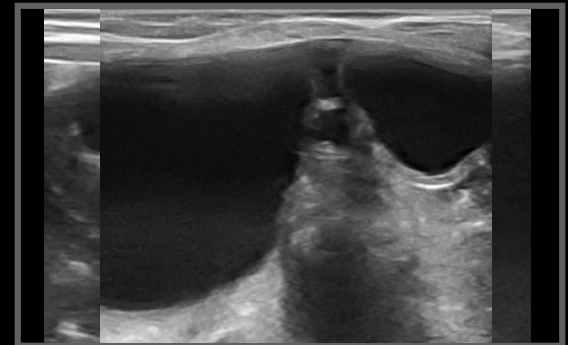
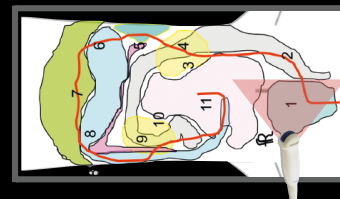

- Distended abdomen
- One episode of vomiting
- Less active
- Indoor only



Newton, FI, 16 years



Another patient, to show the position of the probe



Newton, DSH, FI, 16 years

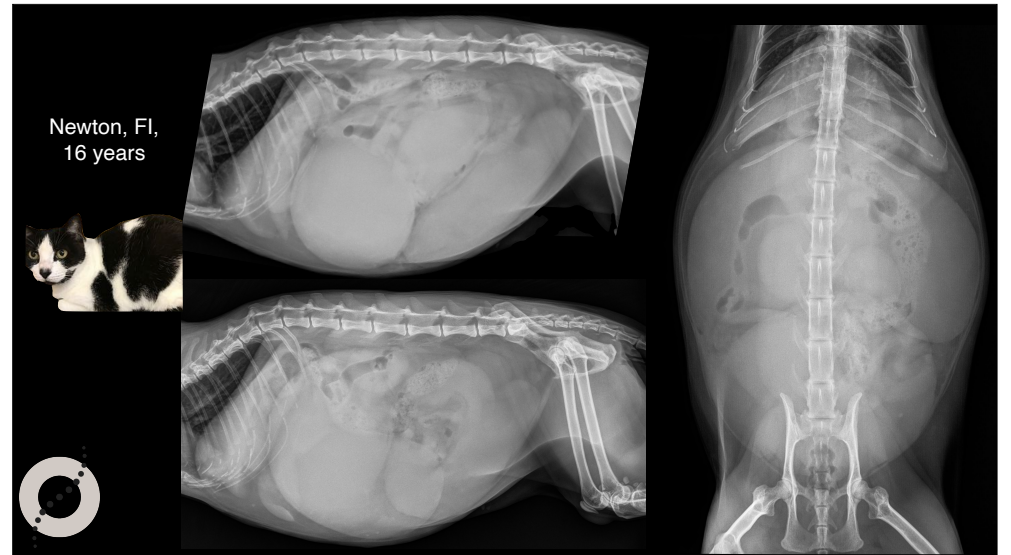
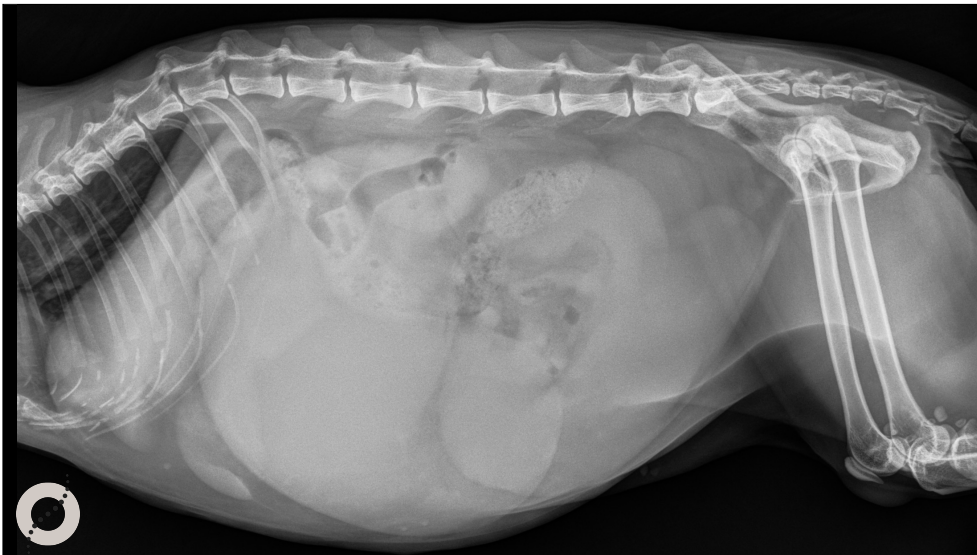
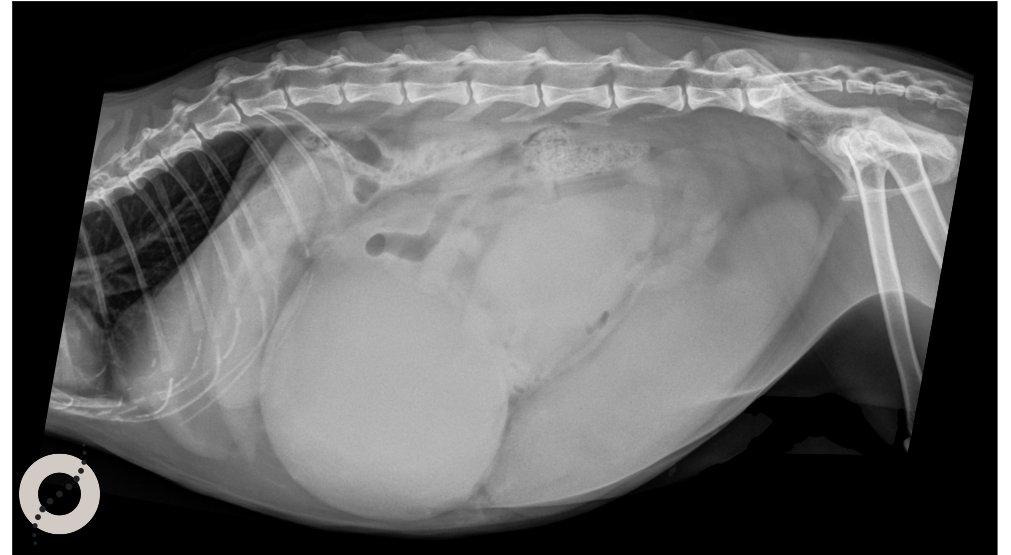
Ultrasonographic diagnoses:

- "Double" urinary bladder, only one has a neck region
- Cystic structure inside a fluid filled structure?
- The kidneys were unremarkable for the age
- Uterus not seen, could be involved?



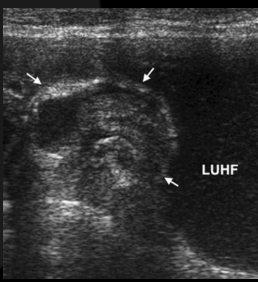
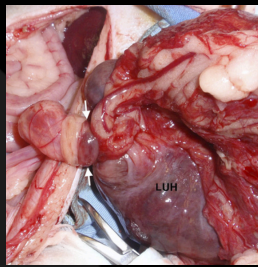
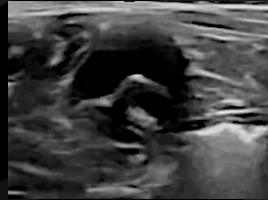
Conclusions:

- ???
- Pyometra/hydrometra?



Uterine torsion

- Pregnancy predisposing factor
- One overdistended by fluid horn
- Focal eccentric “lump”



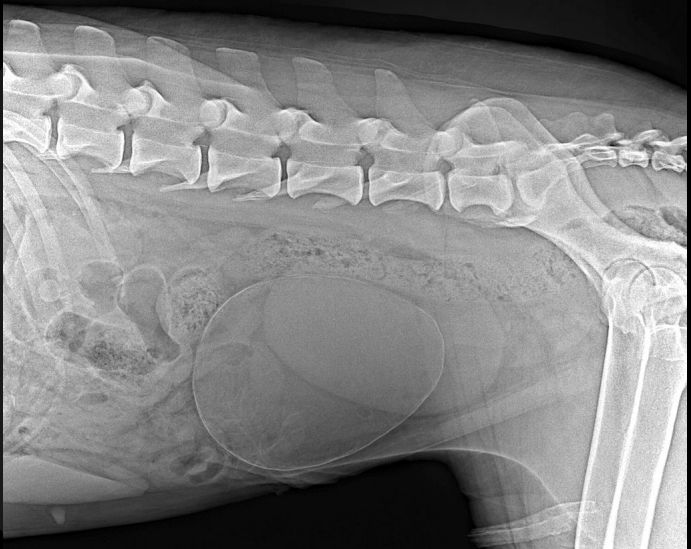
[Bilateral segmental aplasia with unilateral uterine horn torsion in a Pomeranian bitch.](#)
Nakamura K, Yamasaki M, Osaki T, Ohta H, Sasaki N, Aoshima K, Kimura T, Takiguchi M.
J Am Anim Hosp Assoc. 2012 Sep-Oct;48(5):327-30. doi: 10.5326/JAAHA-MS-5771. Epub 2012 Jul 27.
PMID: 22843825

Leone, Maremmano, MI, 7 years

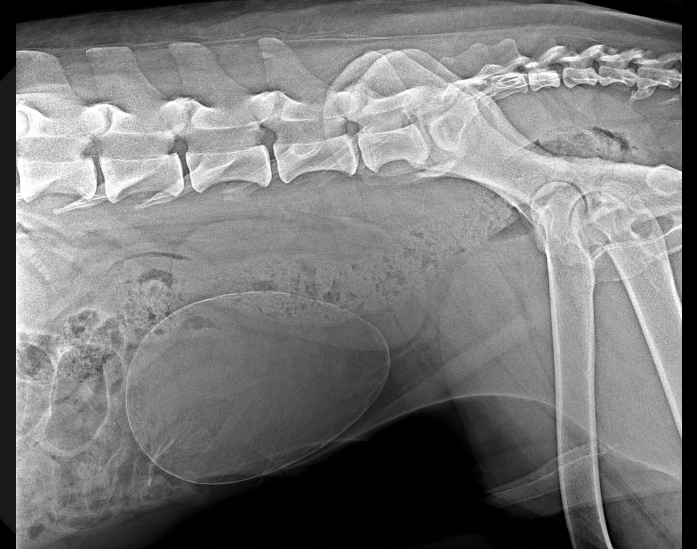- Urinary incontinence
- Chemically castrated
- Weight loss
- Large mass palpated in the caudal abdomen



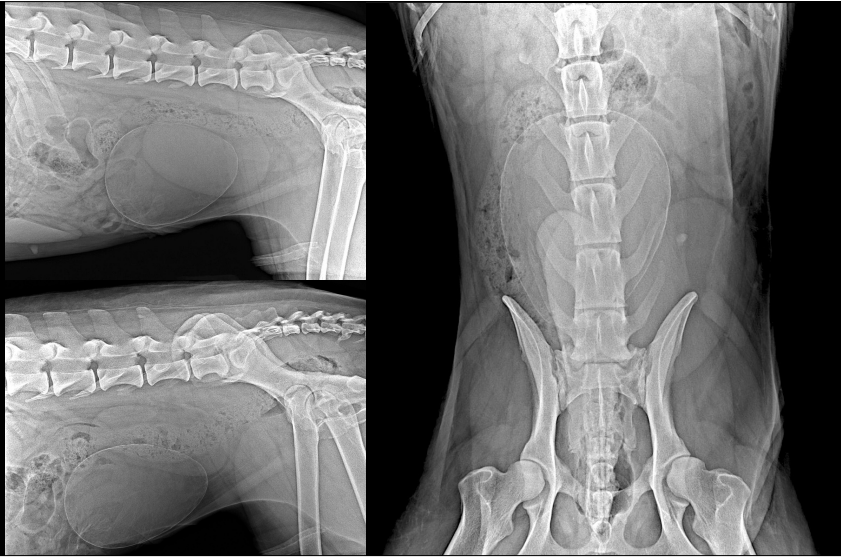
Leone, MI, 7 years



Leone, MI, 7 years

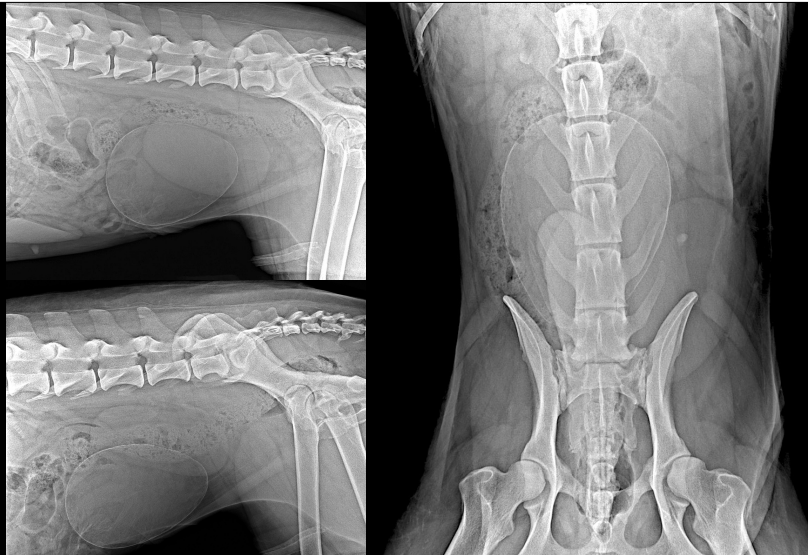

Leone, MI, 7 years



Your evaluation?

Leone, MI, 7 years



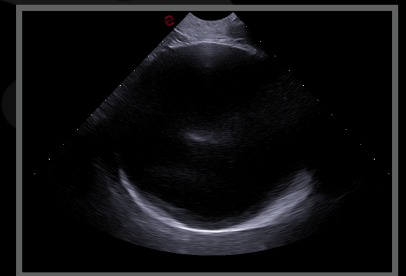
Leone, Maremmano, MI, 7 years

Radiographic diagnoses:

- Oval mineralise structure in the caudal abdomen

Conclusions

- Paraprostatic cyst



PubMed®

mineralized paraprostatic cyst dog

Advanced Create alert Create RSS User Guide

Save Email Send to Sort by: Best match Display options

MY CUSTOM FILTERS

9 results

RESULTS BY YEAR

PUBLICATION DATE

1 year
5 years
10 years
Custom Range

TEXT AVAILABILITY

Inguinal herniation of a mineralized paraprostatic cyst in a dog.

1 Vititoe KP, Grosso FV, Thomovsky S, Lim CK, Heng HG.
Cite Can Vet J. 2017 Dec;58(12):1309-1312.
PMID: 29203942 **Free PMC article.**
Share A firm mass was noted in the right inguinal subcutaneous region of an 11-year-old intact male Labrador retriever **dog** presented for right pelvic limb weakness. Pelvic radiographs showed 2 large ovoid structures with circumferential thin eggshell-like **mineralization** i ...

Mineralized paraprostatic cyst as a potential contributing factor in the development of perineal hernias in a dog.

2 Head LL, Francis DA.
Cite J Am Vet Med Assoc. 2002 Aug 15;221(4):533-5, 500. doi: 10.2460/javma.2002.221.533.
PMID: 12184704 **Free article.**
Share In **dogs** with perineal hernias and tenesmus it is important to include rectal and prostatic diseases, including **paraprostatic cysts**, in the differential list of potential underlying causes. ...Preferred treatment of a **paraprostatic cyst** is surgic ...

CASE REPORT

SMALL ANIMALS

Surgical excision and omentalisation of mineralised paraprostatic cysts with concurrent ureteroneocystostomy and perineal herniorrhaphy in a 9-year-old male entire Bearded Collie

WB Moses* and AE Tipler

Aust Vet J 2025;103:22-26

Omentalisation should be performed in all cases of paraprostatic cyst resection where possible due to the omental support of local immune function, improvement of lymphatic drainage and promotion of angiogenesis.³⁰ In this case, histopathology showed evidence of chronic prostatitis which has previously been reported to occur concurrently in dogs with paraprostatic cysts.^{8,34} Benign prostatic hyperplasia was also present, which is unsurprising given that up to 95% of intact male dogs have evidence of hyperplasia by 9 years of age.¹ In this case, neither culture of the cystic fluid nor tissue was performed, however, one study reported positive bacterial cultures in 42% of dogs with prostatic cysts.³⁵ The presence of paraprostatic cysts and underlying benign prostatic hyperplasia may have contributed to development of prostatitis. Prostatitis can lead to cystitis, and the presence of chronic prostatitis and mild urinary incontinence likely contributed to the development of a urinary tract infection in this case.^{2,3}

Thank you

Diagnostic Mindset

www.diagnosticmindset.com